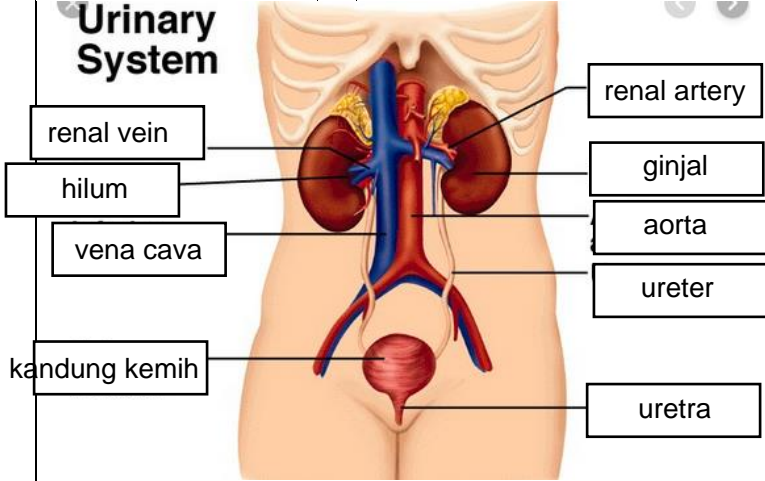
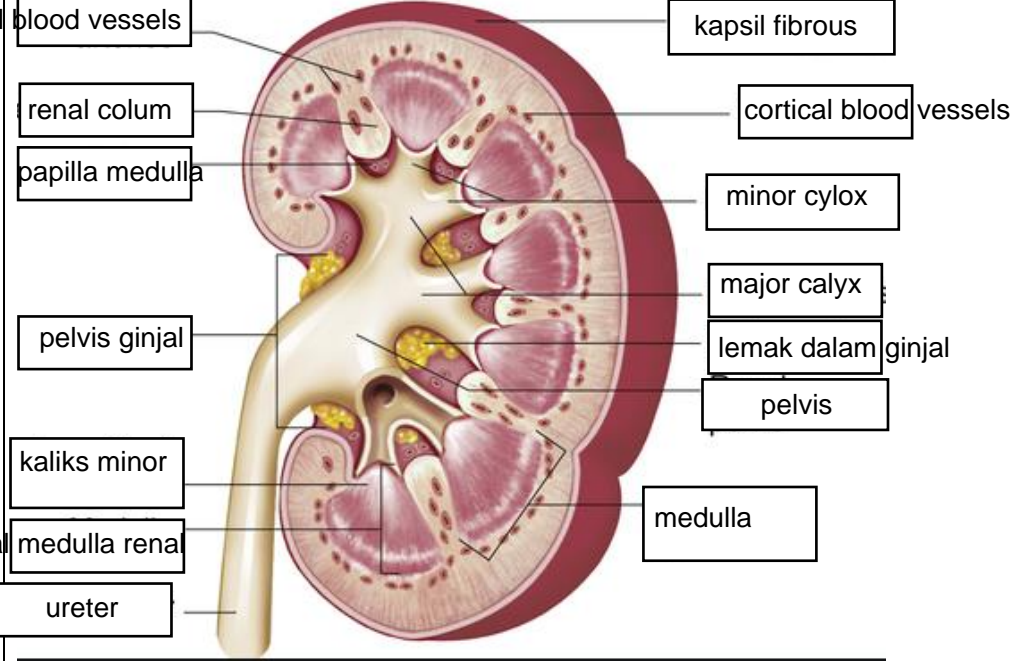


WORKSHEETS (LEMBAR KERJA)

Mata Kuliah	: Anatomi
Materi	: Anatomi Urinari
NIM>Nama Mahasiswa	: 2110101057 / salma safira damayanti

No	Keterangan	Pembahasan
1	<p>Urinary System</p>  <p>renal vein</p> <p>hilum</p> <p>vena cava</p> <p>kandung kemih</p>	<p>renal artery</p> <p>ginjal</p> <p>aorta</p> <p>ureter</p> <p>uretra</p>
cortical	<p>blood vessels</p> <p>renal colum</p> <p>papilla medulla</p> <p>pelvis ginjal</p> <p>kaliks minor</p> <p>medulla renal</p> <p>ureter</p>	 <p>kapsil fibrous</p> <p>cortical blood vessels</p> <p>minor cylox</p> <p>major calyx</p> <p>lemak dalam ginjal</p> <p>pelvis</p> <p>medulla</p>
piramida ginjal		