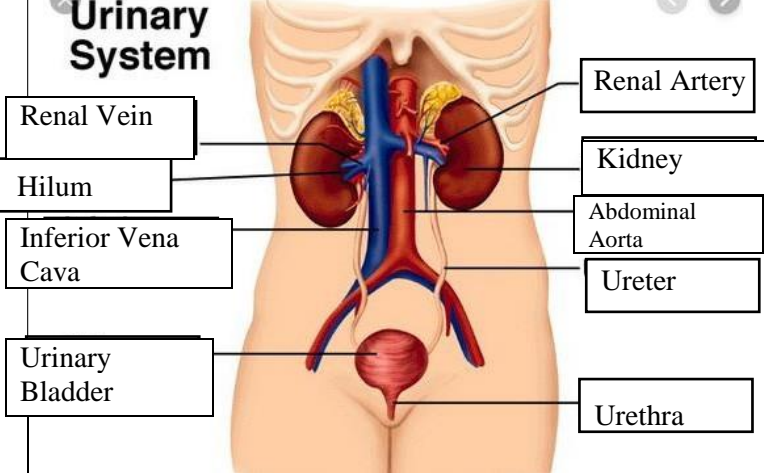
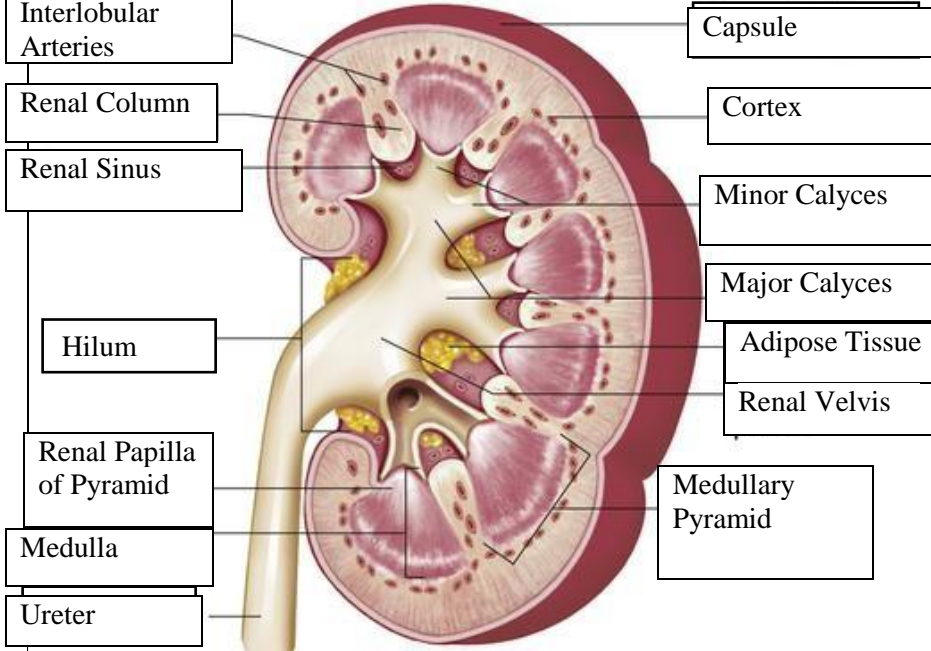


WORKSHEETS (LEMBAR KERJA)

Mata Kuliah	: Anatomi
Materi	: Anatomi Urinari
NIM>Nama Mahasiswa	: 2110101064/ Maulidya Puteri

No	Keterangan	Pembahasan
1	<p>Urinary System</p>  <p>Renal Vein</p> <p>Hilum</p> <p>Inferior Vena Cava</p> <p>Urinary Bladder</p> <p>Renal Artery</p> <p>Kidney</p> <p>Abdominal Aorta</p> <p>Ureter</p> <p>Urethra</p>	
	 <p>Interlobular Arteries</p> <p>Renal Column</p> <p>Renal Sinus</p> <p>Hilum</p> <p>Renal Papilla of Pyramid</p> <p>Medulla</p> <p>Ureter</p> <p>Capsule</p> <p>Cortex</p> <p>Minor Calyces</p> <p>Major Calyces</p> <p>Adipose Tissue</p> <p>Renal Velvis</p> <p>Medullary Pyramid</p>	