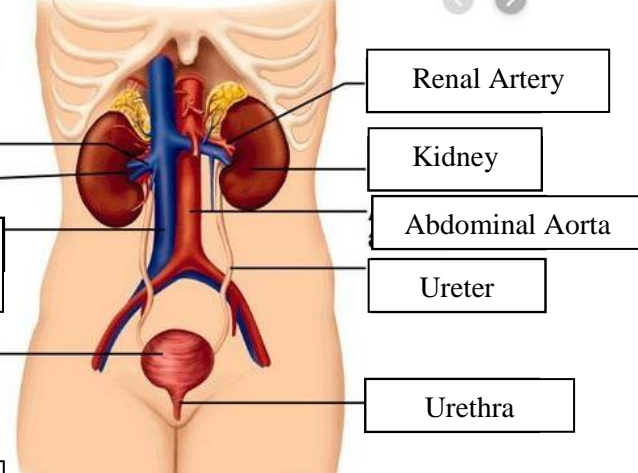
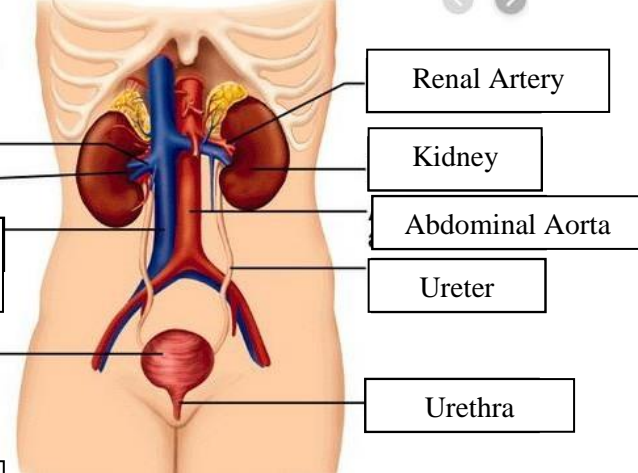
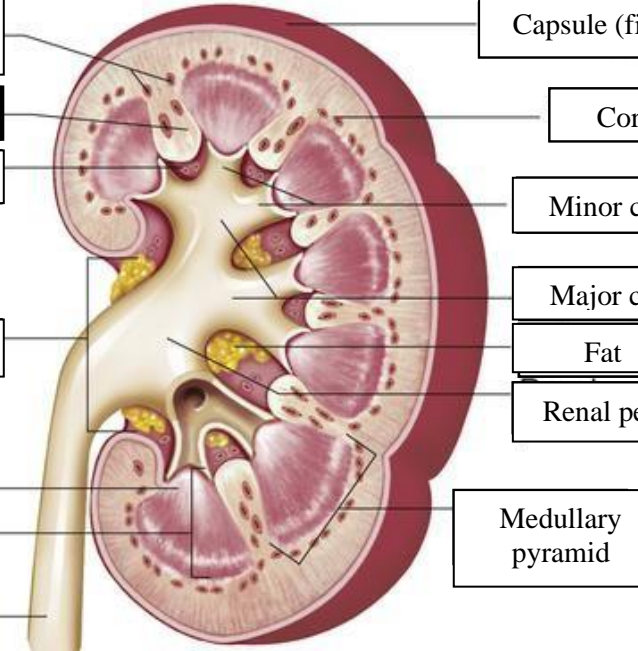


WORKSHEETS (LEMBAR KERJA)

Mata Kuliah	: Anatomi
Materi	: Anatomi Urinari
NIM>Nama Mahasiswa	: 2110101065/Rizfi Pramesi Lalita Fasya

No	Keterangan	Pembahasan
1	<p>Urinary System</p>  <p>Renal vein</p> <p>Hilum</p> <p>Inferior vena cava</p> <p>Urinary bladder</p>	 <p>Renal Artery</p> <p>Kidney</p> <p>Abdominal Aorta</p> <p>Ureter</p> <p>Urethra</p>
	<p>Interlobular arteries</p> <p>Renal column</p> <p>Renal sinus</p> <p>Hilum</p> <p>Renal papilla of pyramid</p> <p>Medulla</p> <p>Ureter</p>	 <p>Capsule (fibrous)</p> <p>Cortex</p> <p>Minor calyces</p> <p>Major calyces</p> <p>Fat</p> <p>Renal pelvis</p> <p>Medullary pyramid</p>