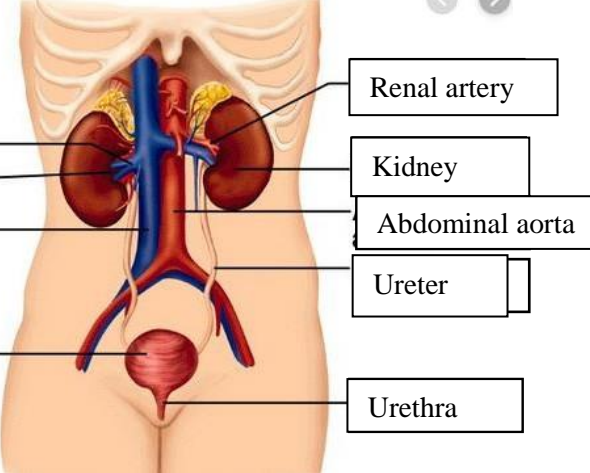
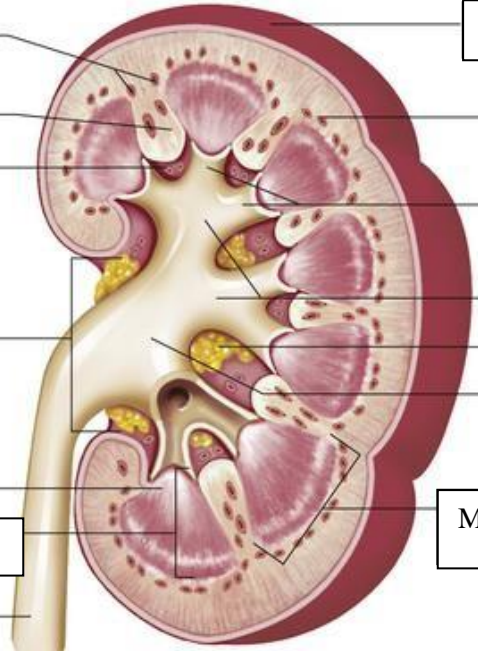


**WORKSHEETS (LEMBAR KERJA)**

<b>Mata Kuliah</b>	: <b>Anatomi</b>
<b>Materi</b>	: <b>Anatomi Urinari</b>
<b>NIM&gt;Nama Mahasiswa</b>	: <b>2110101061/Arum Dea Puspitasari</b>

No	Keterangan	Pembahasan
1	<p><b>Urinary System</b></p>  <p>Labels on the left side of the diagram:</p> <ul style="list-style-type: none"> <li>Renal vein</li> <li>Hilum</li> <li>Inferior vena cava</li> <li>Urinary bladder</li> </ul> <p>Labels on the right side of the diagram:</p> <ul style="list-style-type: none"> <li>Renal artery</li> <li>Kidney</li> <li>Abdominal aorta</li> <li>Ureter</li> <li>Urethra</li> </ul>	
	<p>Cortical blood vessels</p> <p>Renal colum</p> <p>Papilla medulla</p> <p>Pelvis renal</p> <p>Kaliks minor</p> <p>Pyramid renal dalam medulla renal</p> <p>Ureter</p>	 <p>Labels on the right side of the diagram:</p> <ul style="list-style-type: none"> <li>Kapsul fibrous</li> <li>Cortical blood vessels</li> <li>Minor cylox</li> <li>Major calyx</li> <li>Lemak dalam sinus renal</li> <li>Renal pelvis</li> <li>Medulla</li> </ul>