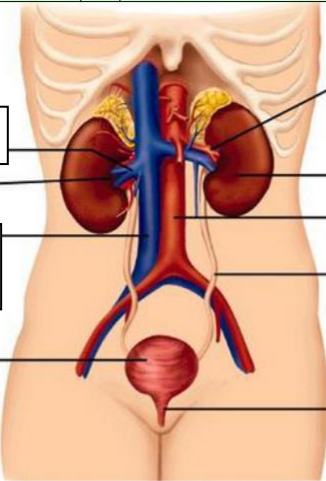
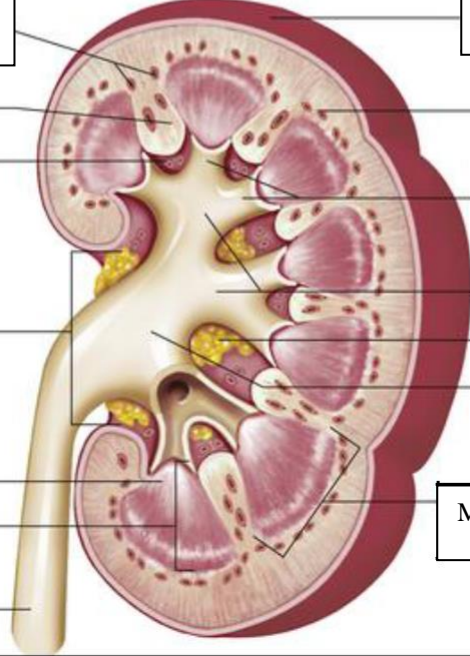


**WORKSHEETS (LEMBAR KERJA)**

<b>Mata Kuliah</b>	: <b>Anatomi</b>
<b>Materi</b>	: <b>Anatomi Urinari</b>
<b>NIM&gt;Nama Mahasiswa</b>	: <b>2110101060/Firsta Fadhila Putri</b>

No	Keterangan	Pembahasan
1	<p><b>Urinary System</b></p>  <p>Renal Vein (Vena ginjal)</p> <p>Hilum</p> <p>Inferior vena cava (vena cava inferior)</p> <p>Urinary bladder (kantong kemih)</p>	<p>Renal artery (Arteri ginjal)</p> <p>Kidney (Ginjal)</p> <p>Abdominal aorta</p> <p>Ureter</p> <p>Urethra</p>
	<p>Cortical blood vessels (pembuluh darah korteks)</p> <p>Ruang renal</p> <p>Sinus renal</p> <p>Renal hilum</p> <p>Renal papila</p> <p>Renal medula</p> <p>ureter</p>	 <p>Kapsul fibrous</p> <p>Renal lobe</p> <p>Minor calyces</p> <p>Major calyces</p> <p>Adipose tissue in renal sinus</p> <p>Renal pelvis</p> <p>Medulla</p>