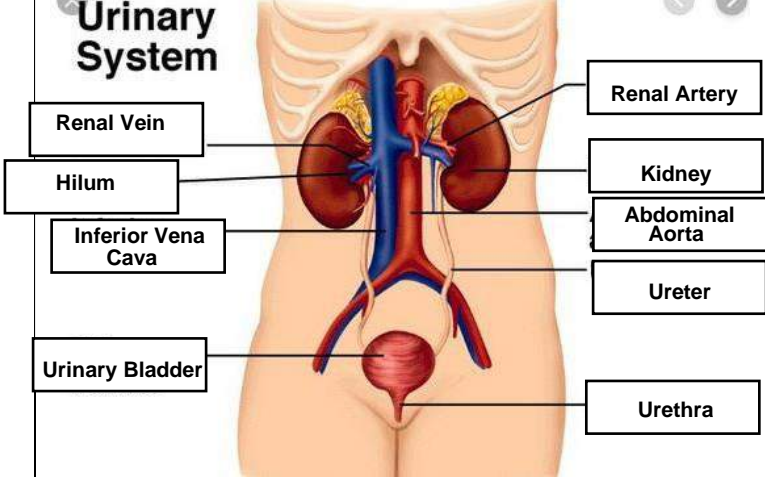
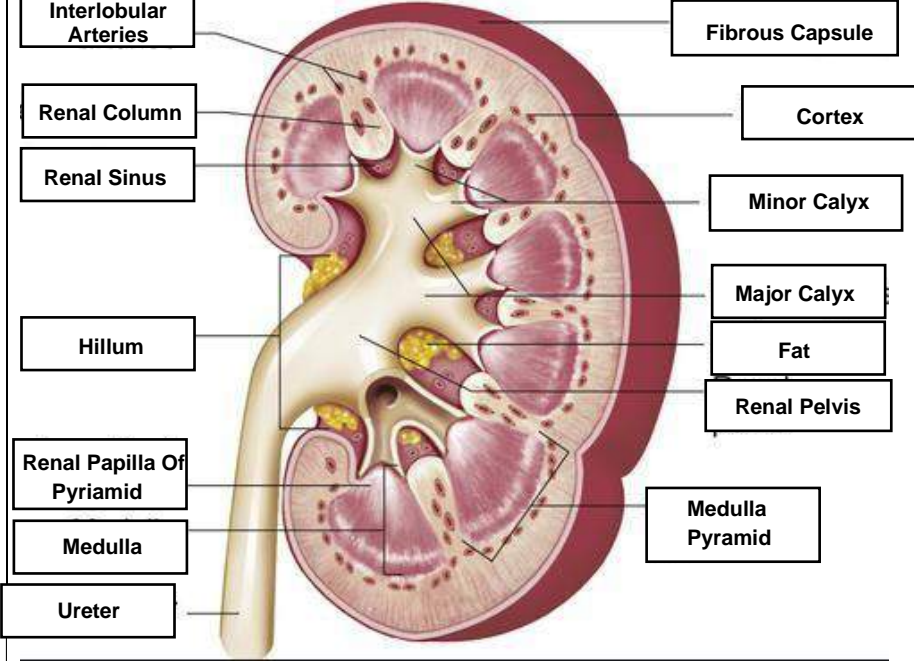


**WORKSHEETS (LEMBAR KERJA)**

<b>Mata Kuliah</b>	: <b>Anatomi</b>
<b>Materi</b>	: <b>Anatomi Urinari</b>
<b>NIM&gt;Nama Mahasiswa</b>	: <b>2110101005/RHANI ROSALINA</b>

No	Keterangan	Pembahasan
1	<p><b>Urinary System</b></p>  <p>Labels on the left: Renal Vein, Hilum, Inferior Vena Cava, Urinary Bladder.</p> <p>Labels on the right: Renal Artery, Kidney, Abdominal Aorta, Ureter, Urethra.</p>	
	 <p>Labels on the left: Interlobular Arteries, Renal Column, Renal Sinus, Hillum, Renal Papilla Of Pyriamid, Medulla, Ureter.</p> <p>Labels on the right: Fibrous Capsule, Cortex, Minor Calyx, Major Calyx, Fat, Renal Pelvis, Medulla Pyramid.</p>	