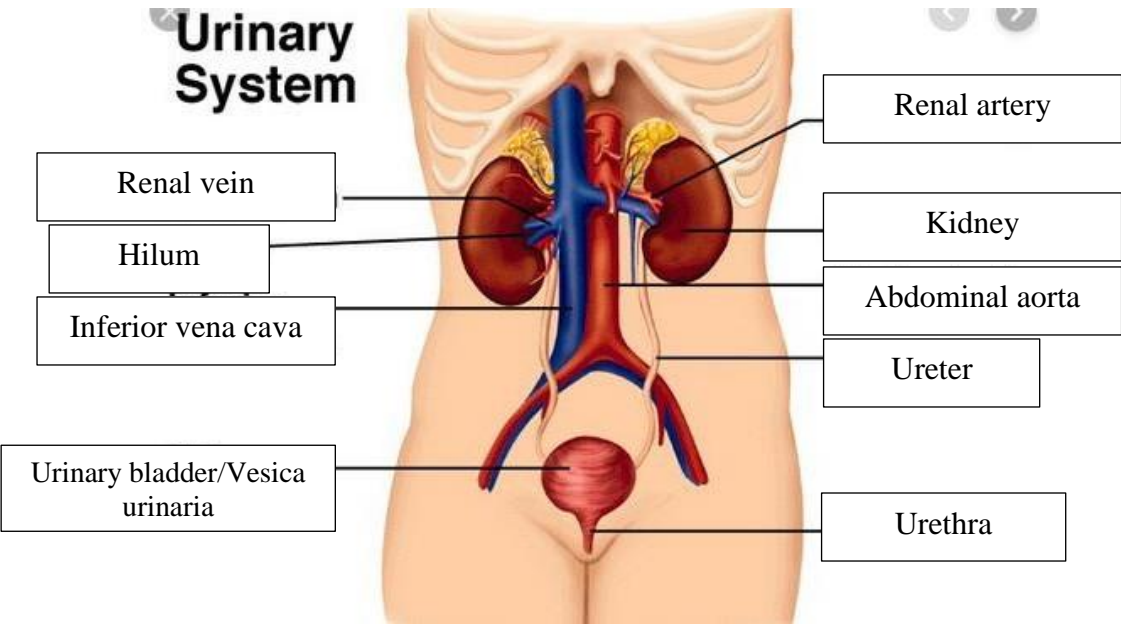
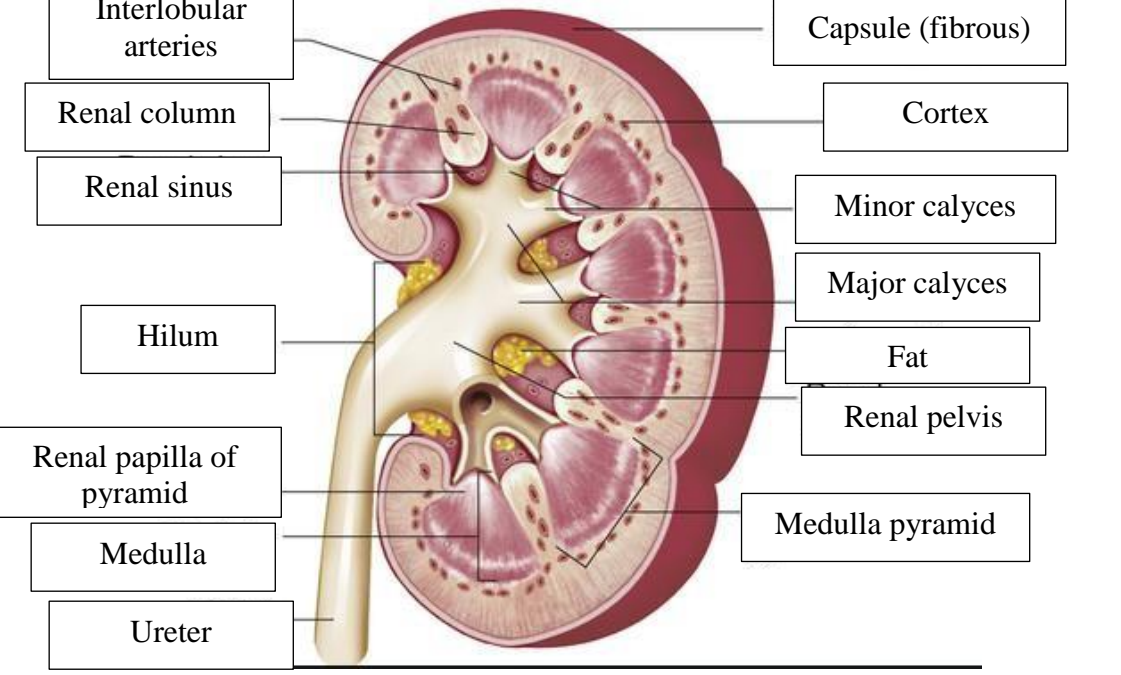


**WORKSHEETS (LEMBAR KERJA)**

<b>Mata Kuliah</b>	: <b>Anatomi</b>
<b>Materi</b>	: <b>Anatomi Urinari</b>
<b>NIM&gt;Nama Mahasiswa</b>	: <b>2110101009/Azira Syiffa Ramadhani</b>

No	Keterangan	Pembahasan
1.		 <p><b>Urinary System</b></p> <ul style="list-style-type: none"> <li>Renal vein</li> <li>Hilum</li> <li>Inferior vena cava</li> <li>Urinary bladder/Vesica urinaria</li> <li>Renal artery</li> <li>Kidney</li> <li>Abdominal aorta</li> <li>Ureter</li> <li>Urethra</li> </ul>
2.		 <ul style="list-style-type: none"> <li>Interlobular arteries</li> <li>Renal column</li> <li>Renal sinus</li> <li>Hilum</li> <li>Renal papilla of pyramid</li> <li>Medulla</li> <li>Ureter</li> <li>Capsule (fibrous)</li> <li>Cortex</li> <li>Minor calyces</li> <li>Major calyces</li> <li>Fat</li> <li>Renal pelvis</li> <li>Medulla pyramid</li> </ul>