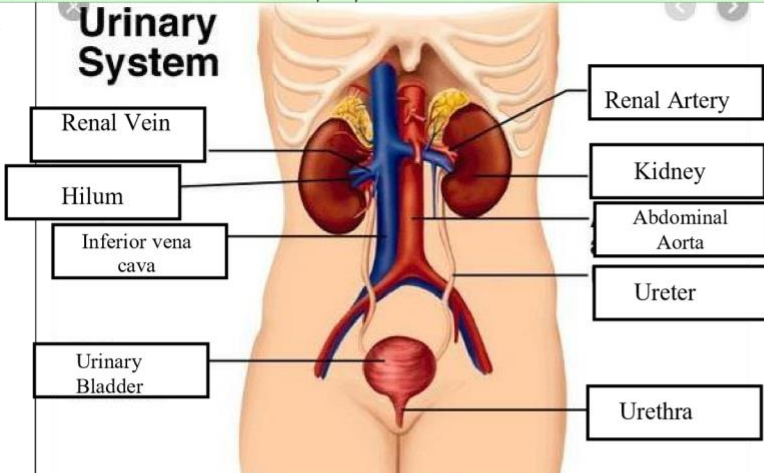
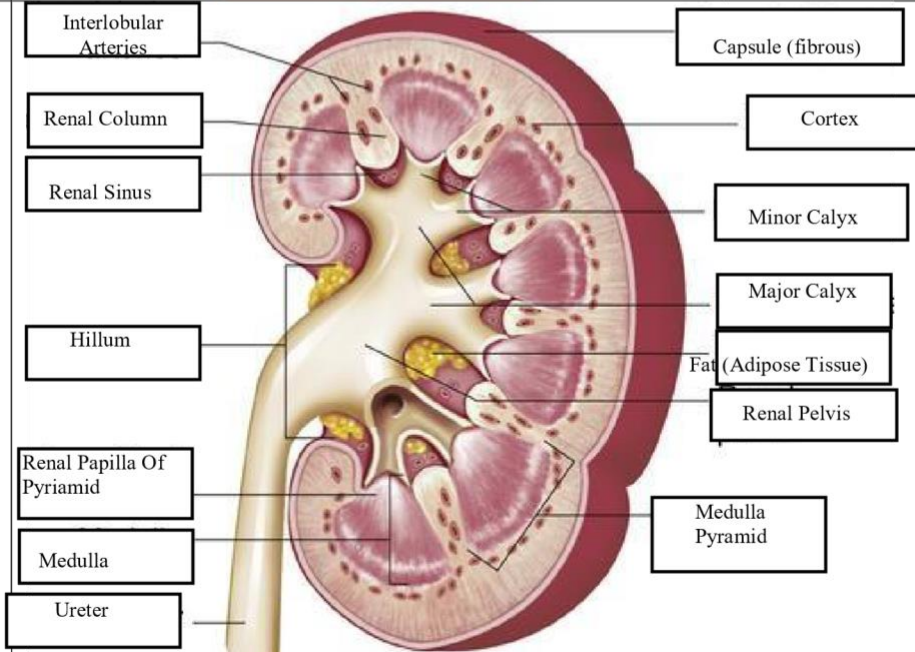


**WORKSHEETS (LEMBAR KERJA)**

<b>Mata Kuliah</b>	<b>: Anatomi</b>
<b>Materi</b>	<b>: Anatomi Urinari</b>
<b>NIM&gt;Nama Mahasiswa</b>	<b>: 2110101042/Suci wulandari</b>

No	Keterangan	Pembahasan
1	<p><b>Urinary System</b></p>  <p>Labels on the left side of the diagram:</p> <ul style="list-style-type: none"> <li>Renal Vein</li> <li>Hilum</li> <li>Inferior vena cava</li> <li>Urinary Bladder</li> </ul> <p>Labels on the right side of the diagram:</p> <ul style="list-style-type: none"> <li>Renal Artery</li> <li>Kidney</li> <li>Abdominal Aorta</li> <li>Ureter</li> <li>Urethra</li> </ul>	
	 <p>Labels on the left side of the diagram:</p> <ul style="list-style-type: none"> <li>Interlobular Arteries</li> <li>Renal Column</li> <li>Renal Sinus</li> <li>Hilum</li> <li>Renal Papilla Of Pyramid</li> <li>Medulla</li> <li>Ureter</li> </ul> <p>Labels on the right side of the diagram:</p> <ul style="list-style-type: none"> <li>Capsule (fibrous)</li> <li>Cortex</li> <li>Minor Calyx</li> <li>Major Calyx</li> <li>Fat (Adipose Tissue)</li> <li>Renal Pelvis</li> <li>Medulla Pyramid</li> </ul>	