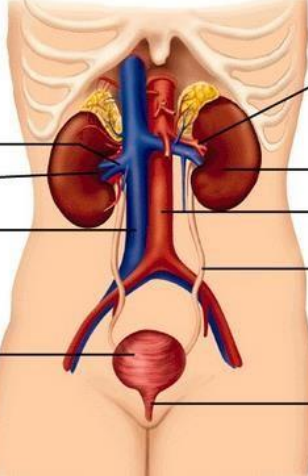
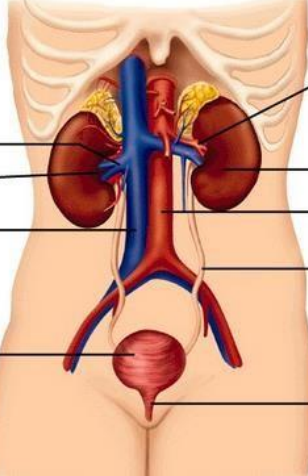
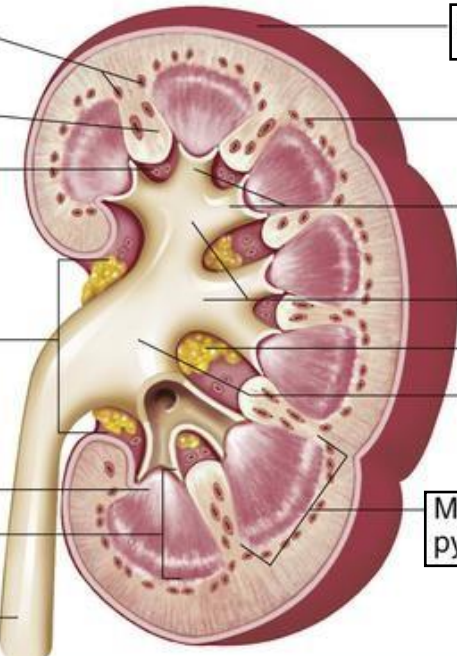


**WORKSHEETS (LEMBAR KERJA)**

<b>Mata Kuliah</b>	<b>: Anatomi</b>
<b>Materi</b>	<b>: Anatomi Urinari</b>
<b>NIM&gt;Nama Mahasiswa</b>	<b>: 2110101053/Fitriyanti Jaya</b>

No	Keterangan	Pembahasan
1	<p><b>Urinary System</b></p>  <p>Renal Vein</p> <p>Hilum</p> <p>Inferior Vena Cava</p> <p>Urinary Bladder</p>	 <p>Renal artery Renal Artery</p> <p>Kidney</p> <p>Abdominal aorta</p> <p>Ureter Ureter</p> <p>Urethra Urethra</p>
	<p>Interlobular Arteries</p> <p>Renal Column</p> <p>Renal Sinus</p> <p>Hilum</p> <p>Renal Papilla of Pyramid</p> <p>Medulla</p> <p>Ureter</p>	 <p>Capsule (fibrous) Fibrous Capsule</p> <p>Cortex</p> <p>Minor calyx Minor Calyx</p> <p>Major calyx Major Calyx</p> <p>Fat</p> <p>Renal Pelvis</p> <p>Medulla Pyramid</p>