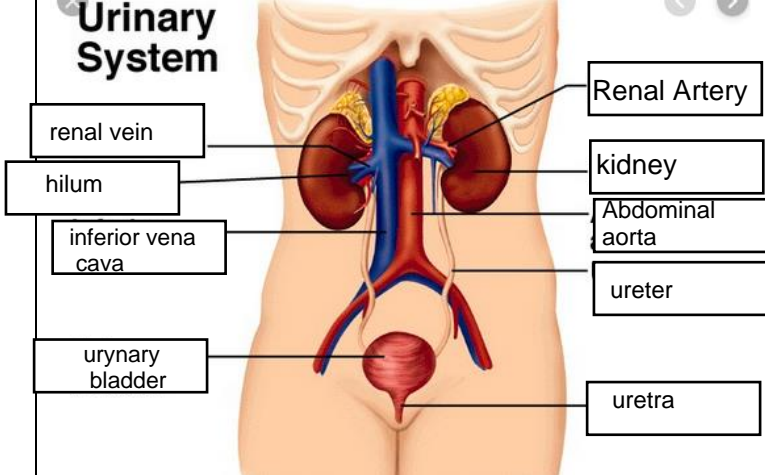
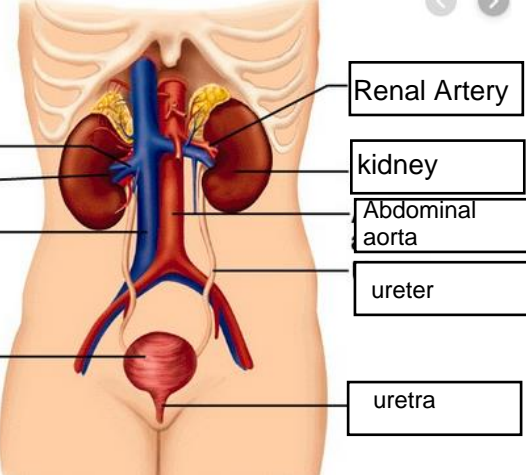
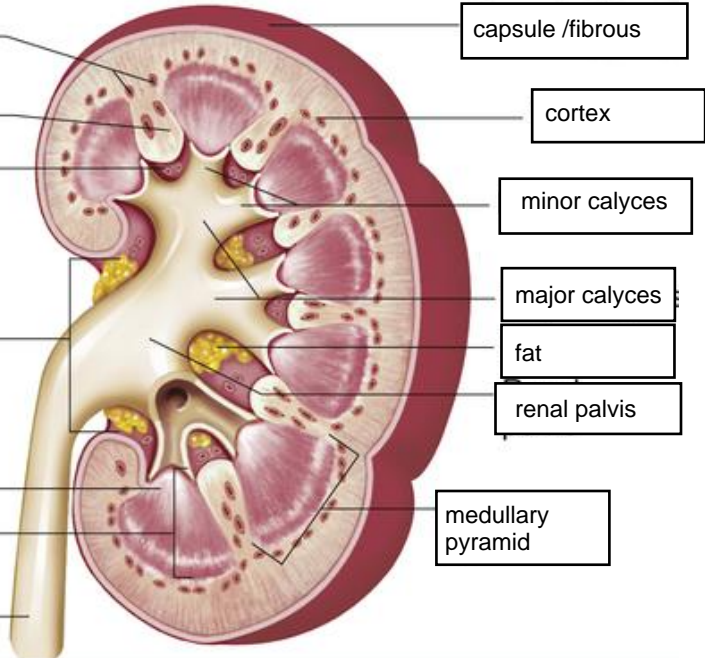


**WORKSHEETS (LEMBAR KERJA)**

<b>Mata Kuliah</b>	: <b>Anatomi</b>
<b>Materi</b>	: <b>Anatomi Urinari</b>
<b>NIM&gt;Nama Mahasiswa</b>	: <b>Izza syifa wahyu salfaira / 2110101032</b>

No	Keterangan	Pembahasan
1	<p><b>Urinary System</b></p>  <p>renal vein</p> <p>hilum</p> <p>inferior vena cava</p> <p>urinary bladder</p>	 <p>Renal Artery</p> <p>kidney</p> <p>Abdominal aorta</p> <p>ureter</p> <p>uretra</p>
	<p>interlobular arteries</p> <p>renal column</p> <p>renal sinus</p> <p>hilum</p> <p>renal papilla of pyramid</p> <p>medula</p> <p>ureter</p>	 <p>capsule /fibrous</p> <p>cortex</p> <p>minor calyces</p> <p>major calyces</p> <p>fat</p> <p>renal palvis</p> <p>medullary pyramid</p>