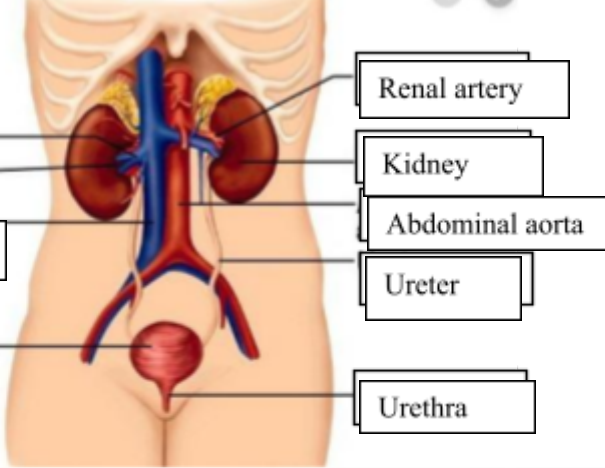
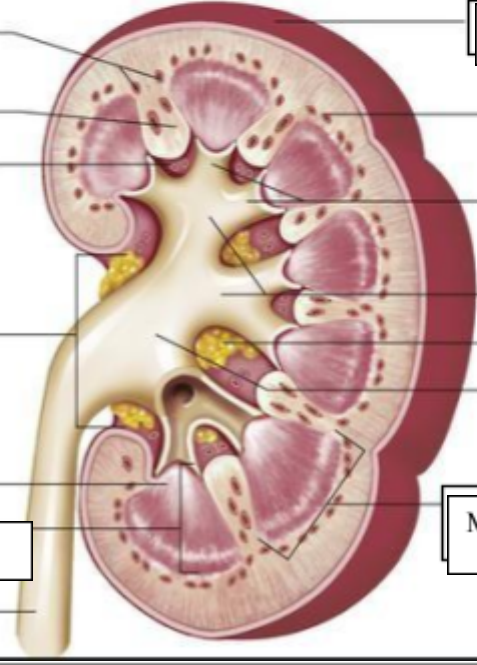


**WORKSHEETS (LEMBAR KERJA)**

<b>Mata Kuliah</b>	: Anatomi
<b>Materi</b>	: Anatomi Urinari
<b>NIM&gt;Nama Mahasiswa</b>	: 2110101077/Putri Anggraini

No	Keterangan	Pembahasan
1	<p><b>Urinary System</b></p>  <p>Labels on the left: Renal vein, Hilum, Inferior vena cava, Urinary bladder.</p> <p>Labels on the right: Renal artery, Kidney, Abdominal aorta, Ureter, Urethra.</p>	
	 <p>Labels on the left: Cortical blood vessels, Renal colum, Papilla medulla, Pelvis renal, Kaliks minor, Pyramid renal dalam medulla renal, Ureter.</p>	<p>Labels on the right: Kapsul fibrous, Cortical blood vessels, Minor cylox, Major calyx, Lemak dalam sinus renal, Renal pelvis, Medulla.</p>