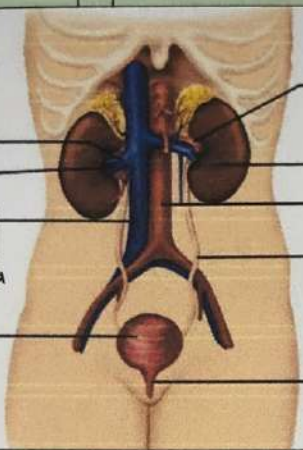


**WORKSHEETS (LEMBAR KERJA)**

Mata Kuliah	: Anatomi
Materi	: Anatomi Urinari
NIM>Nama Mahasiswa	: Halisa Layyinatussyifa / 2110101123

No	Keterangan	Pembahasan
1	<p><b>Urinary System</b></p>  <p>Renal vein</p> <p>Hilum</p> <p>Inferior vena cava</p> <p>Urinary bladder</p>	<p>Renal artery</p> <p>Kidney</p> <p>Abdominal aorta</p> <p>Ureter</p> <p>Urathra</p>
	<p>Interlobular arteries</p> <p>Column</p> <p>Renal sinus</p> <p>Hilum</p> <p>Renal Papilla</p> <p>Medula</p> <p>Ureter</p>	<p>Capsula (Fibrous)</p> <p>Cortex</p> <p>minor calyces</p> <p>Major calyces</p> <p>Fat / Adipose tissue in renal sinus</p> <p>Renal pelvis</p> <p>Medullary pyramid</p>

cortical blood vessels

Ruang Renal/ Renal

Renal lobe

OF Pyramid