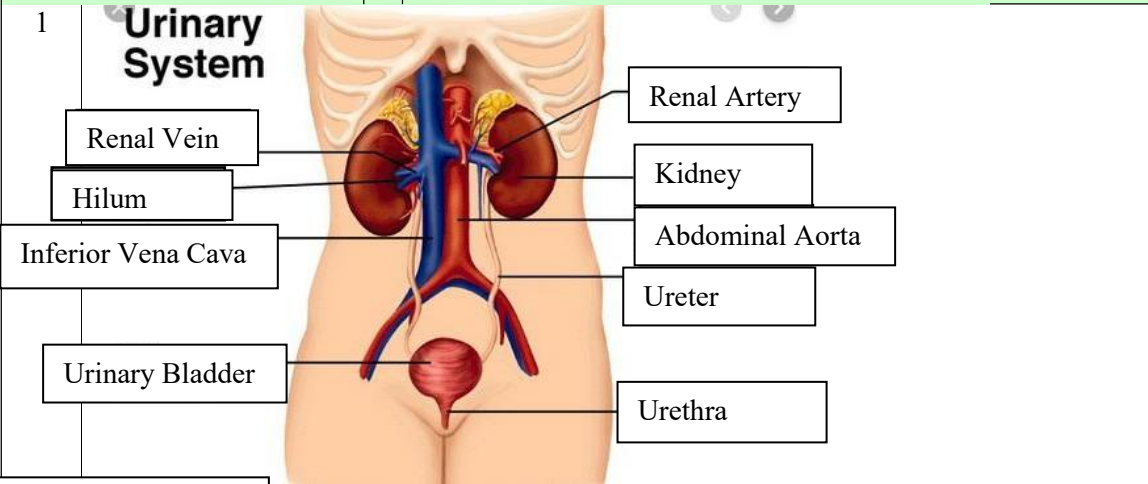
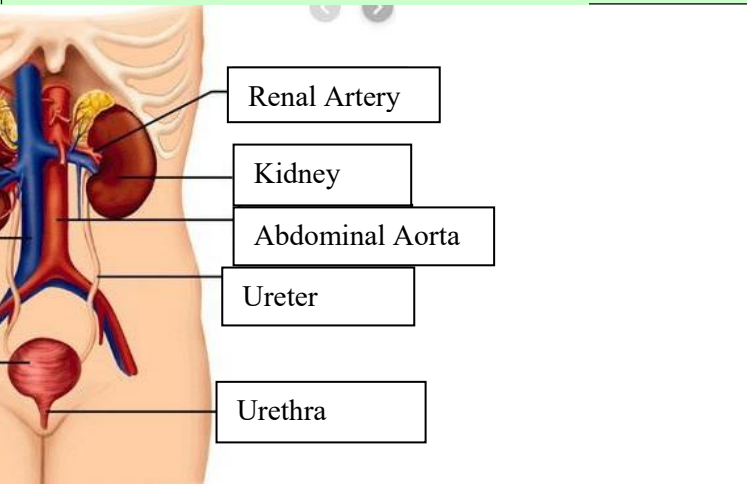
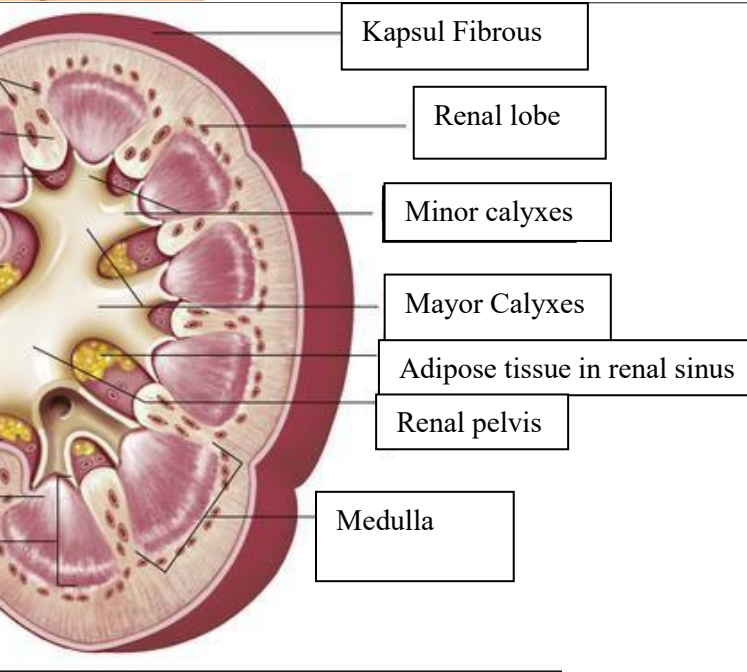


WORKSHEETS (LEMBAR KERJA)

Mata Kuliah	: Anatomi
Materi	: Anatomi Urinari
NIM>Nama Mahasiswa	: 2110101026/Aisyah Mutiara Agustin

No	Keterangan	Pembahasan
1	<p>Urinary System</p>  <p>Renal Vein</p> <p>Hilum</p> <p>Inferior Vena Cava</p> <p>Urinary Bladder</p>	 <p>Renal Artery</p> <p>Kidney</p> <p>Abdominal Aorta</p> <p>Ureter</p> <p>Urethra</p>
	<p>Cortical blood vessels</p> <p>Ruang renal</p> <p>Sinus renal</p> <p>Renal hilum</p> <p>Renal papila</p> <p>Renal medula</p> <p>Ureter</p>	 <p>Kapsul Fibrous</p> <p>Renal lobe</p> <p>Minor calyces</p> <p>Mayor Calyces</p> <p>Adipose tissue in renal sinus</p> <p>Renal pelvis</p> <p>Medulla</p>