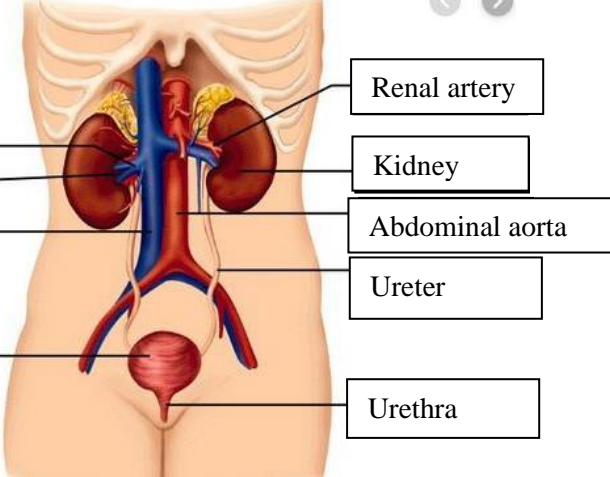
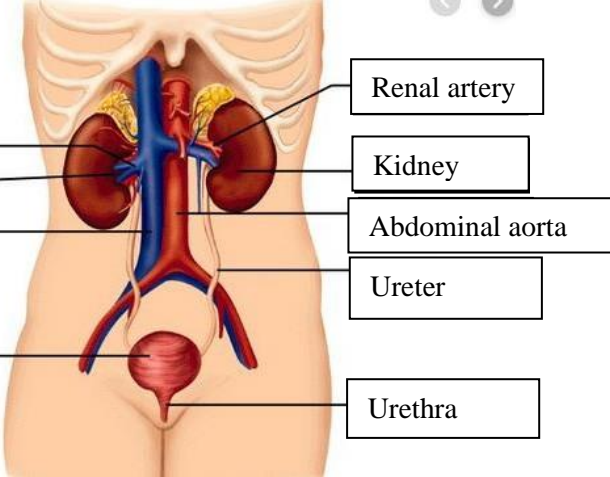
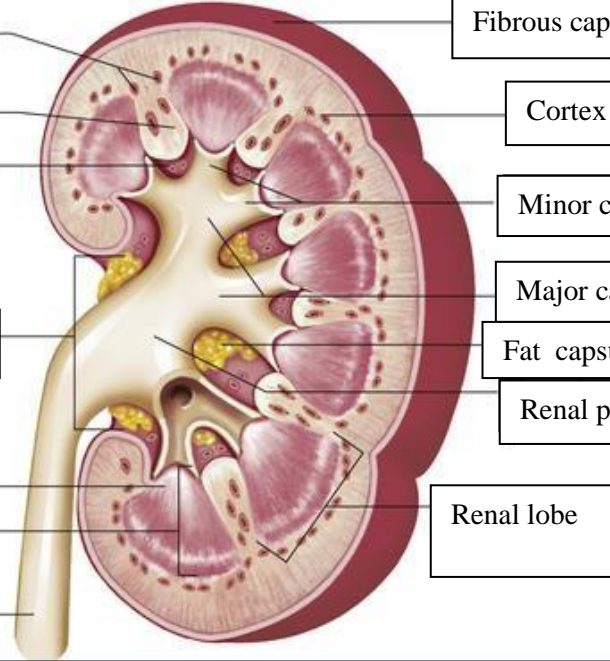


**WORKSHEETS (LEMBAR KERJA)**

<b>Mata Kuliah</b>	: <b>Anatomi</b>
<b>Materi</b>	: <b>Anatomi Urinari</b>
<b>NIM&gt;Nama Mahasiswa</b>	: <b>2110101089/ EVI NOFIANDARI</b>

No	Keterangan	Pembahasan
1	<p><b>Urinary System</b></p>  <p>Renal vein</p> <p>Hilum</p> <p>Inferior vena cava</p> <p>Urinary bladder</p>	 <p>Renal artery</p> <p>Kidney</p> <p>Abdominal aorta</p> <p>Ureter</p> <p>Urethra</p>
	<p>Interlobular arteries</p> <p>Renal column</p> <p>Renal sinus</p> <p>Hilum</p> <p>Renal papilla pyramid</p> <p>medulla</p> <p>Ureter</p>	 <p>Fibrous capsule</p> <p>Cortex</p> <p>Minor calyces</p> <p>Major calyces</p> <p>Fat capsule</p> <p>Renal pelvis</p> <p>Renal lobe</p>