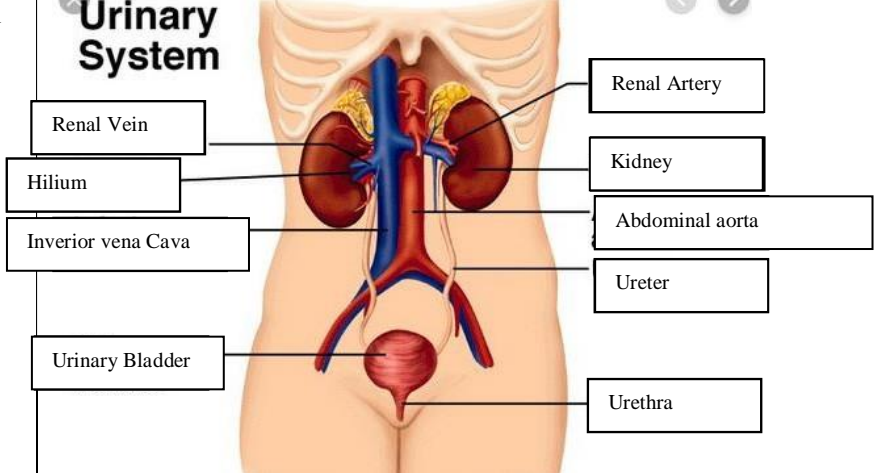
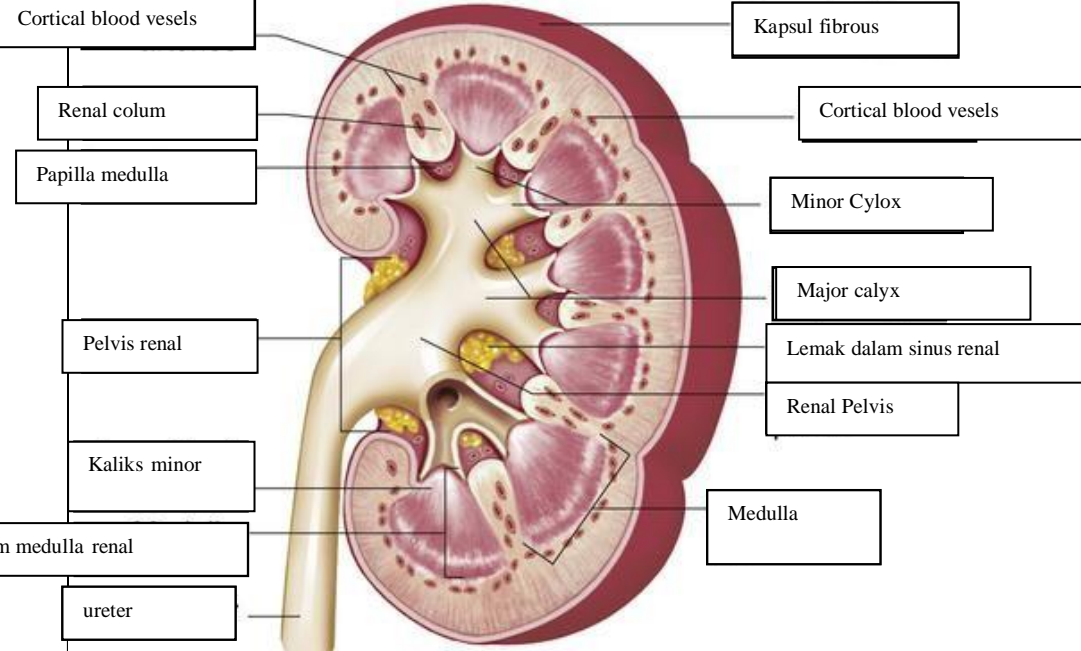


WORKSHEETS (LEMBAR KERJA)

Mata Kuliah	: Anatomi
Materi	: Anatomi Urinari
NIM>Nama Mahasiswa	: 2110101083/Riska Arinanda

No	Keterangan	Pembahasan
1	<p>Urinary System</p>  <p>Labels on the left: Renal Vein, Hilum, Inferior vena Cava, Urinary Bladder.</p> <p>Labels on the right: Renal Artery, Kidney, Abdominal aorta, Ureter, Urethra.</p>	
	<p>Cortical blood vesels</p> <p>Renal colum</p> <p>Papilla medulla</p> <p>Pelvis renal</p> <p>Kaliks minor</p> <p>Pyramid renal dalam medulla renal</p> <p>ureter</p>	 <p>Kapsul fibrous</p> <p>Cortical blood vesels</p> <p>Minor Cylox</p> <p>Major calyx</p> <p>Lemak dalam sinus renal</p> <p>Renal Pelvis</p> <p>Medulla</p>