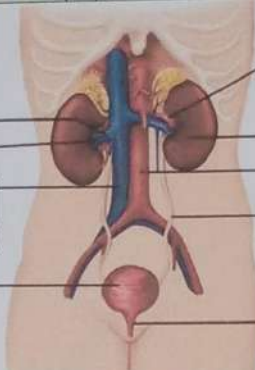
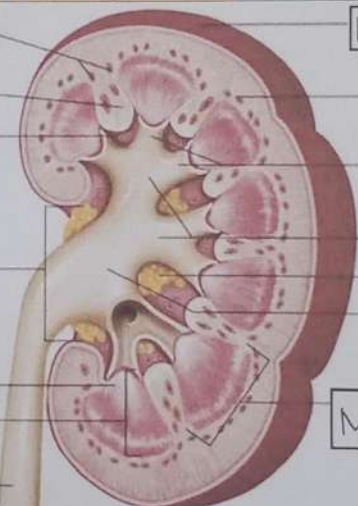


**WORKSHEETS (LEMBAR KERJA)**

Mata Kuliah	: Anatomi
Materi	: Anatomi Urinari
NIM>Nama Mahasiswa	: Nindra Arlindawati / 2110101097

No	Keterangan	Pembahasan
1	<p><b>Urinary System</b></p>  <p> <span>Renal Vein</span>  <span>Hilum</span>  <span>Inferior Vena cava</span>  <span>Urinary Bladder</span> </p>	<p> <span>Renal Artery</span>  <span>Kidney</span>  <span>Abdominal Aorta</span>  <span>Ureter</span>  <span>Urethra</span> </p>
	<p><b>Cortical</b></p>  <p> <span>blood vessels</span>  <span>Renal Column</span>  <span>Papilla Medulla</span>  <span>Pelvis Renal</span>  <span>Kaliks MINOR</span>  <span>Pyramid renal dlm medulla renal</span>  <span>Ureter</span> </p>	<p> <span>kapsul Fibrous</span>  <span>Cortical blood vessels</span>  <span>Minor Calyx</span>  <span>Major Calyx</span>  <span>Lemak dlm sinus renal</span>  <span>Renal Pelvis</span>  <span>Medulla</span> </p>