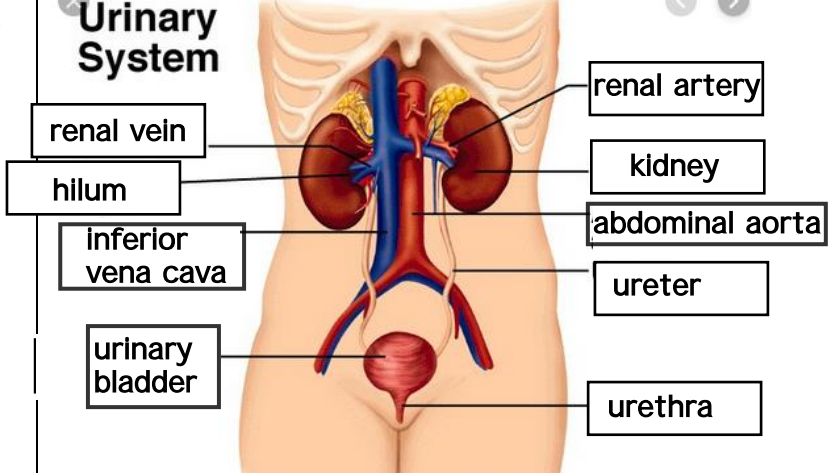
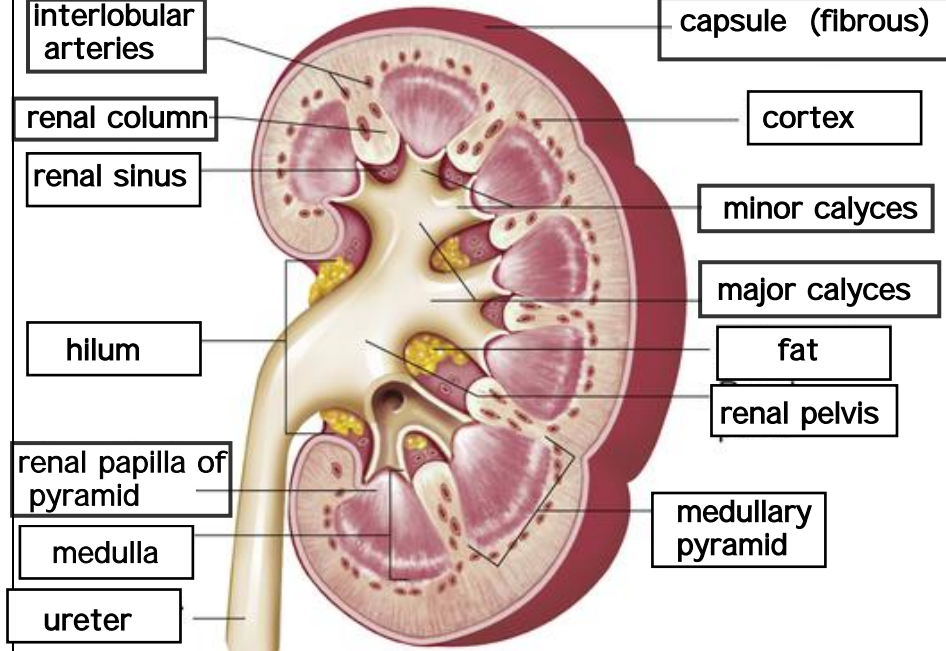


**WORKSHEETS (LEMBAR KERJA)**

Mata Kuliah	: Anatomi
Materi	: Anatomi Urinari
NIM>Nama Mahasiswa	: selina agustin siswandi 2110101130

No	Keterangan	Pembahasan
1	<p><b>Urinary System</b></p>  <p>renal vein</p> <p>hilum</p> <p>inferior vena cava</p> <p>urinary bladder</p> <p>renal artery</p> <p>kidney</p> <p>abdominal aorta</p> <p>ureter</p> <p>urethra</p>	
	 <p>interlobular arteries</p> <p>renal column</p> <p>renal sinus</p> <p>hilum</p> <p>renal papilla of pyramid</p> <p>medulla</p> <p>ureter</p> <p>capsule (fibrous)</p> <p>cortex</p> <p>minor calyces</p> <p>major calyces</p> <p>fat</p> <p>renal pelvis</p> <p>medullary pyramid</p>	