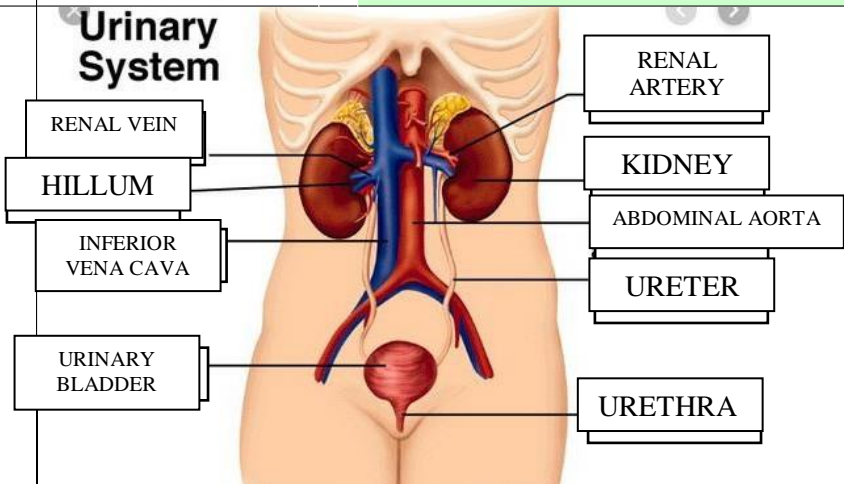
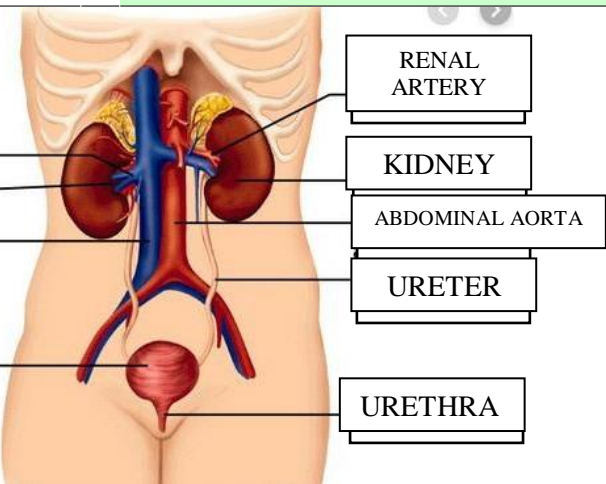
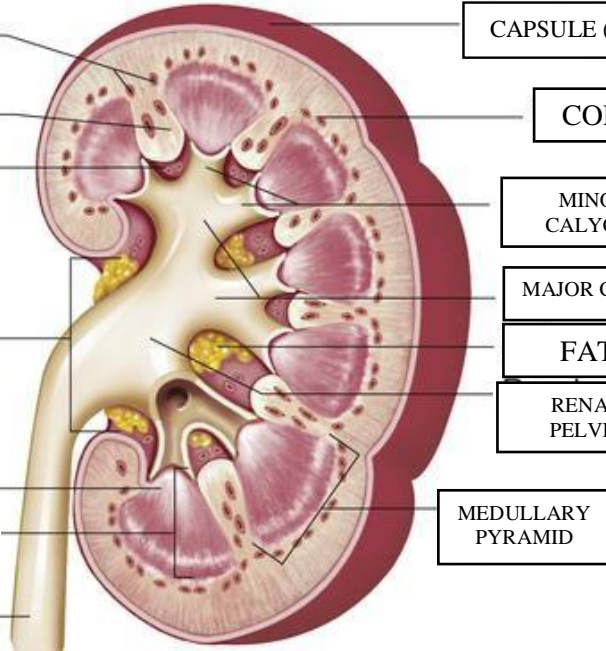


WORKSHEETS (LEMBAR KERJA)

Mata Kuliah	: Anatomi
Materi	: Anatomi Urinari
NIM>Nama Mahasiswa	: 2110101082/SITI MAESARAH

No	Keterangan	Pembahasan
1	<p>Urinary System</p>  <p>RENAL VEIN</p> <p>HILLUM</p> <p>INFERIOR VENA CAVA</p> <p>URINARY BLADDER</p>	 <p>RENAL ARTERY</p> <p>KIDNEY</p> <p>ABDOMINAL AORTA</p> <p>URETER</p> <p>URETHRA</p>
	<p>INTERLOBULAR ARTERIES</p> <p>RENAL COLUMN</p> <p>RENAL SINUS</p> <p>HILUM</p> <p>RENAL PAPILLA OF PYRAMID</p> <p>MEDULLA</p> <p>URETER</p>	 <p>CAPSULE (FIBROUS)</p> <p>CORTEX</p> <p>MINOR CALYCES</p> <p>MAJOR CALYCELS</p> <p>FAT</p> <p>RENAL PELVIS</p> <p>MEDULLARY PYRAMID</p>