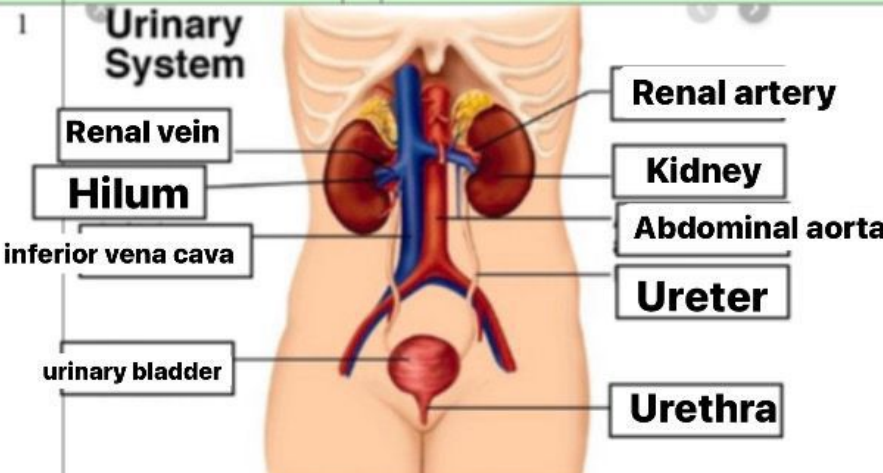
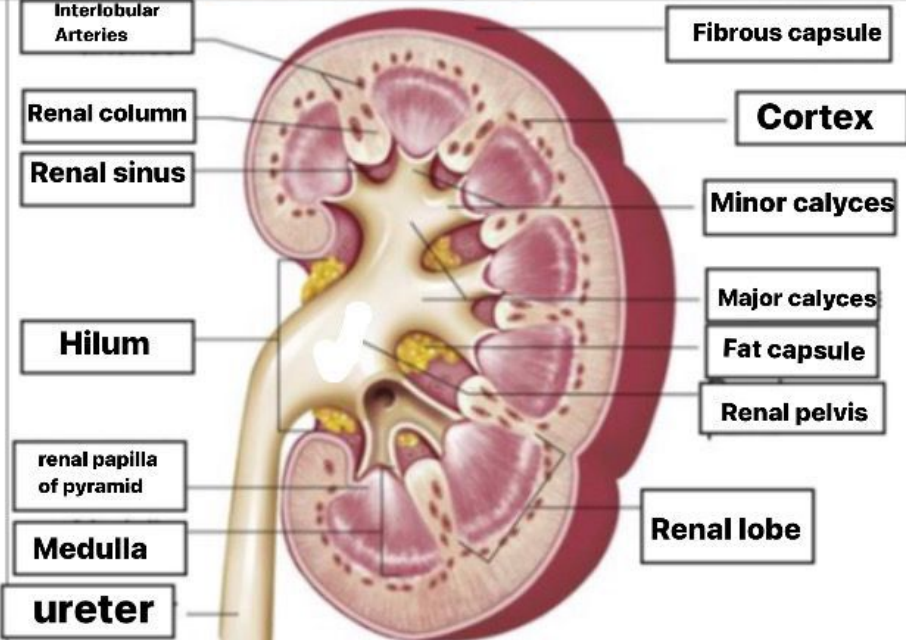


**WORKSHEETS (LEMBAR KERJA)**

Mata Kuliah	: Anatomi
Materi	: Anatomi Urinari
NIM>Nama Mahasiswa	: 2110101114 /salsa alima azzahra

No	Keterangan	Pembahasan
1	<p><b>Urinary System</b></p>  <p>Labels on the left: Renal vein, Hilum, inferior vena cava, urinary bladder</p> <p>Labels on the right: Renal artery, Kidney, Abdominal aorta, Ureter, Urethra</p>	
	 <p>Labels on the left: Interlobular Arteries, Renal column, Renal sinus, Hilum, renal papilla of pyramid, Medulla, ureter</p> <p>Labels on the right: Fibrous capsule, Cortex, Minor calyces, Major calyces, Fat capsule, Renal pelvis, Renal lobe</p>	