

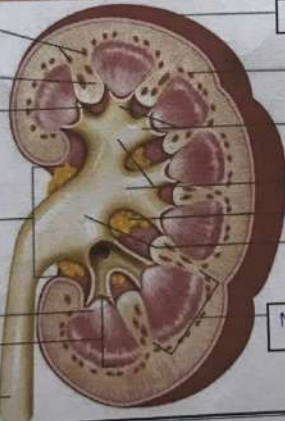
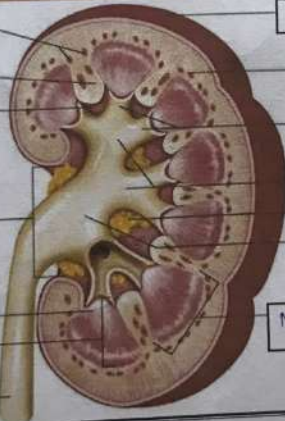


**WORKSHEETS (LEMBAR KERJA)**

Mata Kuliah	: Anatomi
Materi	: Anatomi Urinari
NIM>Nama Mahasiswa	: Tiara Sinta A

No	Keterangan	Pembahasan
1	<p><b>Urinary System</b></p>  <p>Renal vein</p> <p>Hilum</p> <p>Inferior vena cava</p> <p>Urinary bladder</p>	 <p>Renal artery</p> <p>Kidney</p> <p>Abdominal aorta</p> <p>Ureter</p> <p>Urethra</p>
	 <p>Interlobular arteries</p> <p>renal column</p> <p>Renal sinus</p> <p>Hilum</p> <p>Renal papilla of pyramid</p> <p>Medulla</p> <p>Ureter</p>	 <p>Capsule (fibrous)</p> <p>Cortex</p> <p>Minor calyx</p> <p>Major calyx</p> <p>fat (adipose tissue)</p> <p>Renal pelvis</p> <p>Medulla Pyramid</p>