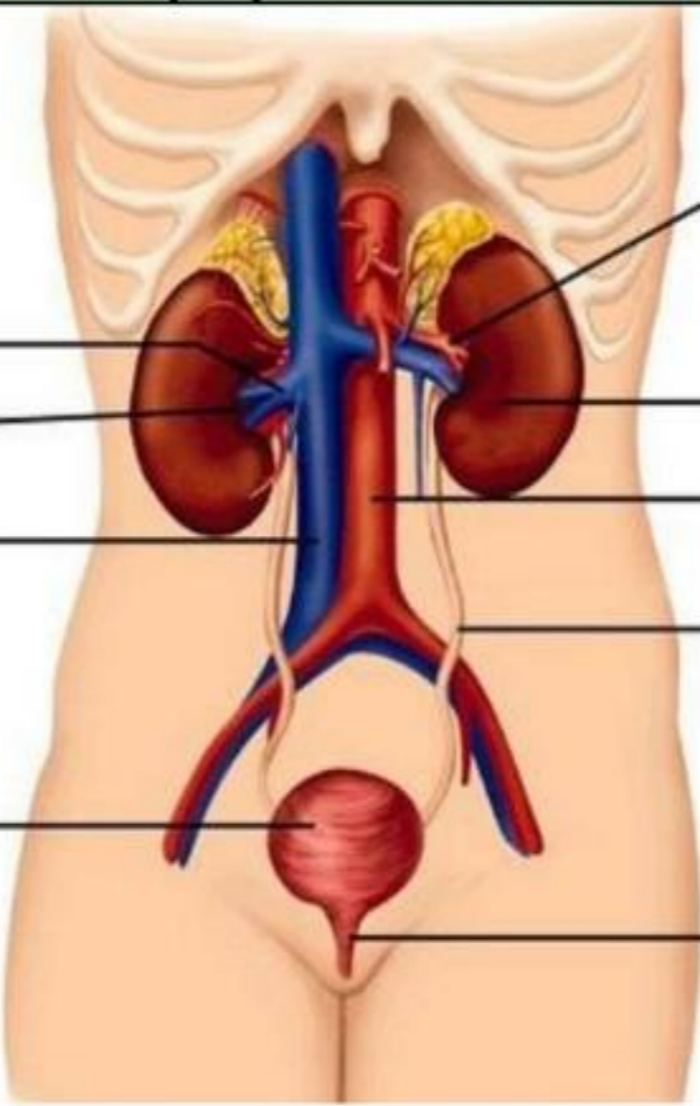
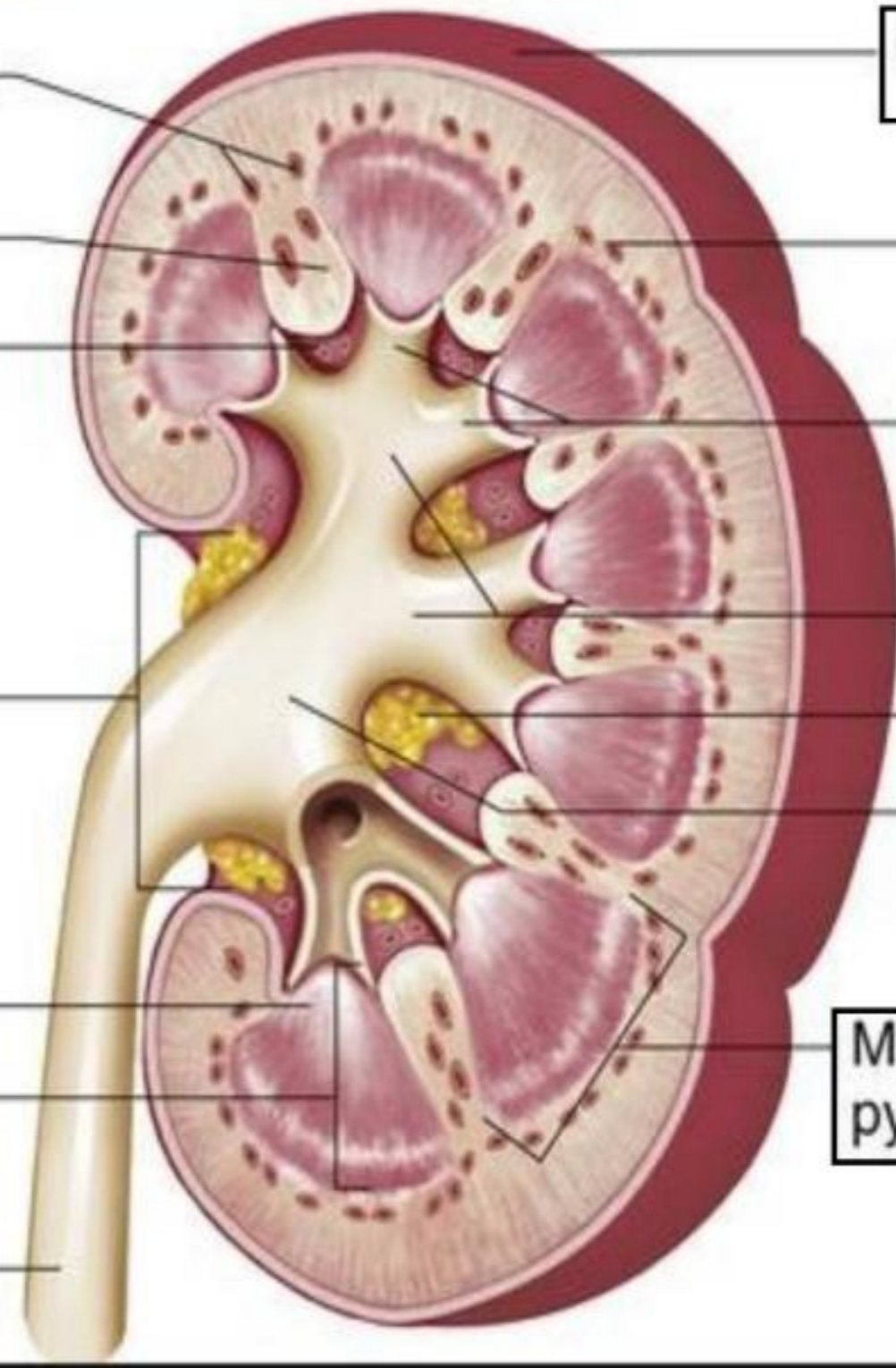


WORKSHEETS (LEMBAR KERJA)

Mata Kuliah	: Anatomi
Materi	: Anatomi Urinari
NIM>Nama Mahasiswa	: 2110101096/Imelda Oktafiani

No	Keterangan	Pembahasan
1	<p>Urinary System</p>  <p>Labels on the left: Renal vein, Hilum, Inferior vena cava, Urinary bladder</p> <p>Labels on the right: Renal artery, Kidney, Abdominal aorta, Ureter, Urethra</p>	
	 <p>Labels on the left: Interlobular arteries, Renal column, Renal sinus, Hilum, Medial papilla of pyramid, Medulla, Ureter</p> <p>Labels on the right: Capsule (fibrous), Cortex, Minor calyces, Major calyces, Fat, Renal pelvis, Medullary pyramid</p>	