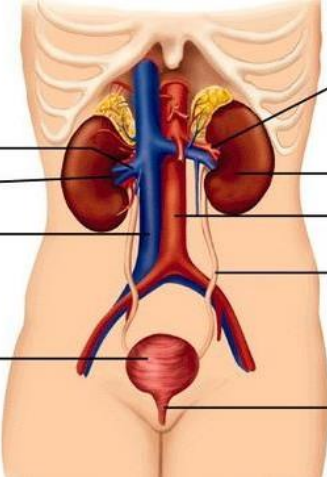
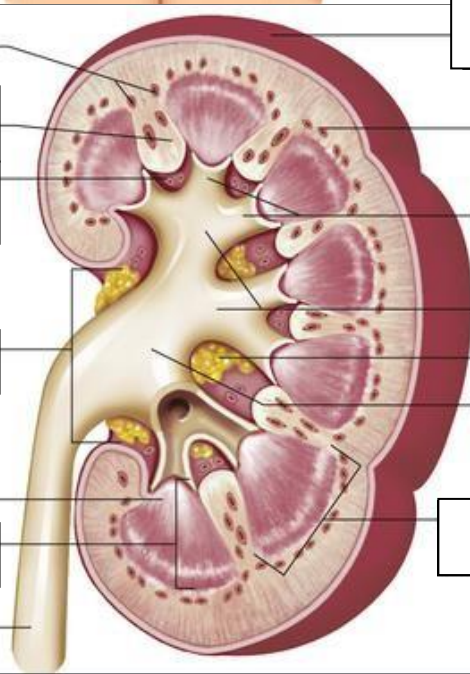


**WORKSHEETS (LEMBAR KERJA)**

<b>Mata Kuliah</b>	: <b>Anatomi</b>
<b>Materi</b>	: <b>Anatomi Urinari</b>
<b>NIM&gt;Nama Mahasiswa</b>	: <b>2110101110/Cici Liara Septi</b>

No	Keterangan	Pembahasan
1	<p><b>Urinary System</b></p>  <p>Right renal vein</p> <p>Right renal artery</p> <p>vena cava inferior</p> <p>Urinary bladder</p>	<p>Left renal artery</p> <p>Ginjal/kidney</p> <p>Aorta</p> <p>Ureter</p> <p>Uretra</p>
	<p>Interlobular arteries</p> <p>Renal column</p> <p>Renal sinus</p> <p>Renal hilum</p> <p>Renal papilla</p> <p>Medulla</p> <p>Ureter</p>	 <p>Renal capsule</p> <p>Cortex</p> <p>Minor calyces</p> <p>Mayor calyces</p> <p>Fat capsule</p> <p>Renal pelvis</p> <p>pyramid</p>