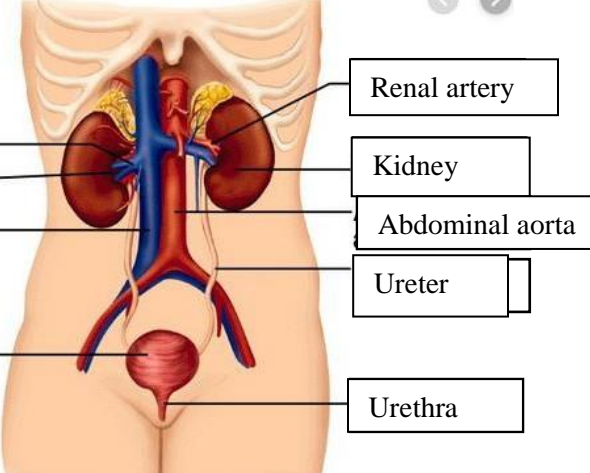
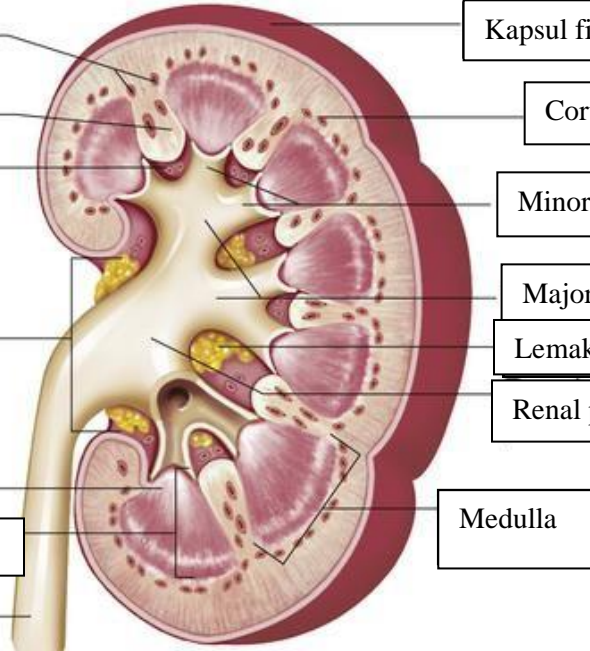


WORKSHEETS (LEMBAR KERJA)

Mata Kuliah	: Anatomi
Materi	: Anatomi Urinari
NIM>Nama Mahasiswa	: 2110101079/Afri Budi Setyaeni

No	Keterangan	Pembahasan
1	<p>Urinary System</p>  <p>Labels on the left: Renal vein, Hilum, Inferior vena cava, Urinary bladder</p> <p>Labels on the right: Renal artery, Kidney, Abdominal aorta, Ureter, Urethra</p>	
	 <p>Labels on the left: Cortical blood vessels, Renal column, Papilla medulla, Pelvis renal, Kaliks minor, Pyramid renal dalam medulla renal, Ureter</p>	<p>Labels on the right: Kapsul fibrous, Cortical blood vessels, Minor cylox, Major calyx, Lemak dalam sinus renal, Renal pelvis, Medulla</p>