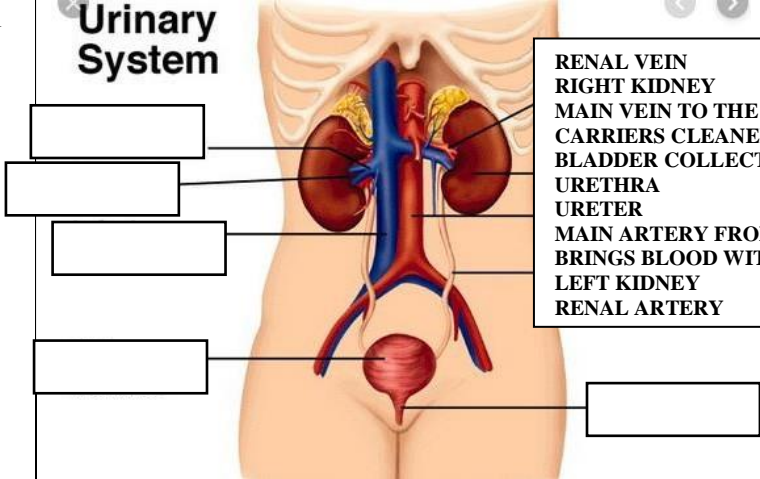
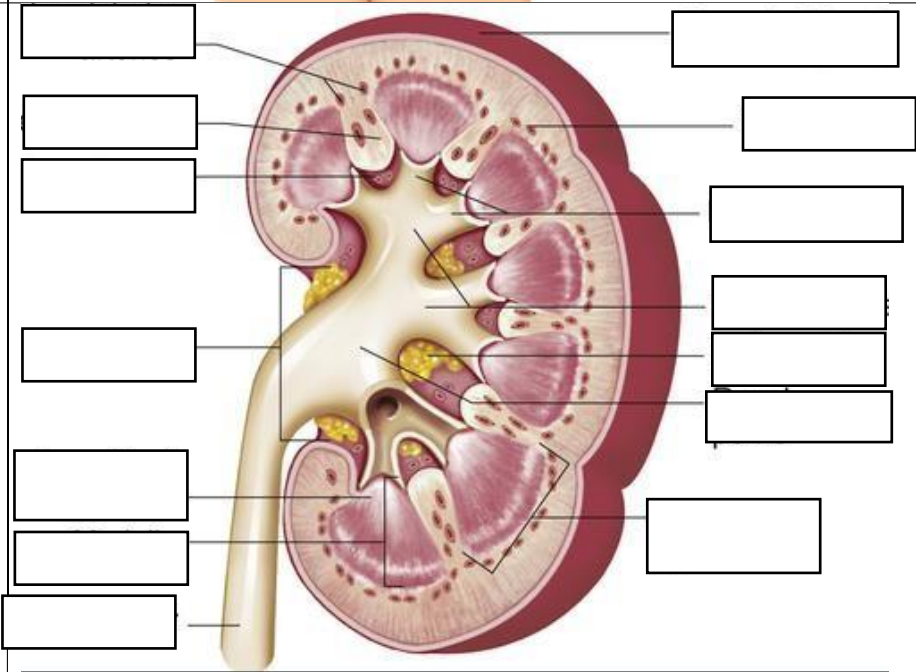


**WORKSHEETS (LEMBAR KERJA)**

<b>Mata Kuliah</b>	: <b>Anatomi</b>
<b>Materi</b>	: <b>Anatomi Urinari</b>
<b>NIM&gt;Nama Mahasiswa</b>	: 2110101106/Fatimah Azzahra

No	Keterangan	Pembahasan
1	<p><b>Urinary System</b></p> 	<div style="border: 1px solid black; padding: 5px;"> <p>RENAL VEIN                      RIGHT KIDNEY                      MAIN VEIN TO THE HEART                      CARRIERS CLEANED BLOOD                      BLADDER COLLECTS URINE                      URETHRA                      URETER                      MAIN ARTERY FROM HEART                      BRINGS BLOOD WITH WASHES                      LEFT KIDNEY                      RENAL ARTERY</p> </div>
		<div style="border: 1px solid black; padding: 5px;"> <p>INTERLOBULAR ARTERIES                      RENAL COLUMN                      RENAL SINUS                      HILUM                      RENAL PAPILLA PYRAMID                      MEDULLA                      URETER                      FIBROUS CAPSULE                      CORTEX                      MINOR CALYCES                      MAJOR CALYCES                      FAT CAPSULE                      RENAL PELVIS                      RENAL LOBE</p> </div>

INTERLOBULAR ARTERIES  
 RENAL COLUMN  
 RENAL SINUS  
 HILUM  
 RENAL PAPILLA PYRAMID  
 MEDULLA  
 URETER  
 FIBROUS CAPSULE  
 CORTEX  
 MINOR CALYCES  
 MAJOR CALYCES  
 FAT CAPSULE  
 RENAL PELVIS  
 RENAL LOBE