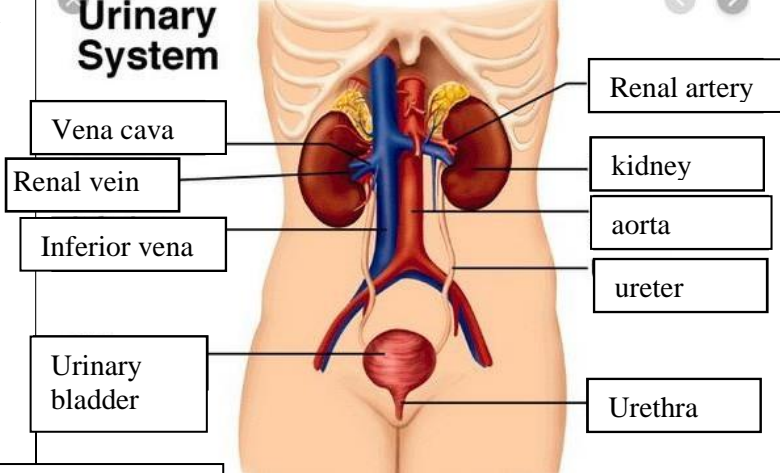
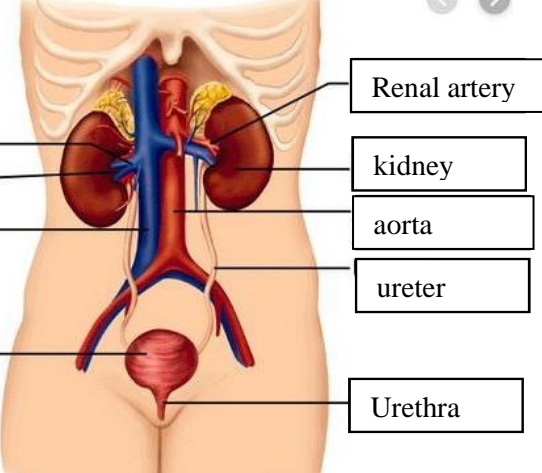
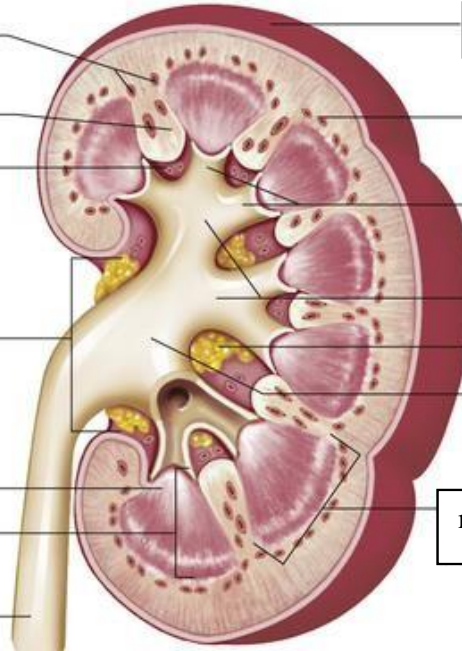


**WORKSHEETS (LEMBAR KERJA)**

<b>Mata Kuliah</b>	: <b>Anatomi</b>
<b>Materi</b>	: <b>Anatomi Urinari</b>
<b>NIM&gt;Nama Mahasiswa</b>	: <b>2110101104/ Lyla aleyda lasawedi</b>

No	Keterangan	Pembahasan
1	<p><b>Urinary System</b></p>  <p>Vena cava</p> <p>Renal vein</p> <p>Inferior vena</p> <p>Urinary bladder</p>	 <p>Renal artery</p> <p>kidney</p> <p>aorta</p> <p>ureter</p> <p>Urethra</p>
	<p>Cortical blood vessels</p> <p>Ruang renal</p> <p>Sinus renal</p> <p>Renal hilum</p> <p>Renal papilla</p> <p>Renal medula</p> <p>ureter</p>	 <p>Kapsul fibrous</p> <p>Renal lobe</p> <p>Minor calyces</p> <p>Major calyces</p> <p>Renal papilla</p> <p>Renal pelvis</p> <p>medulla</p>