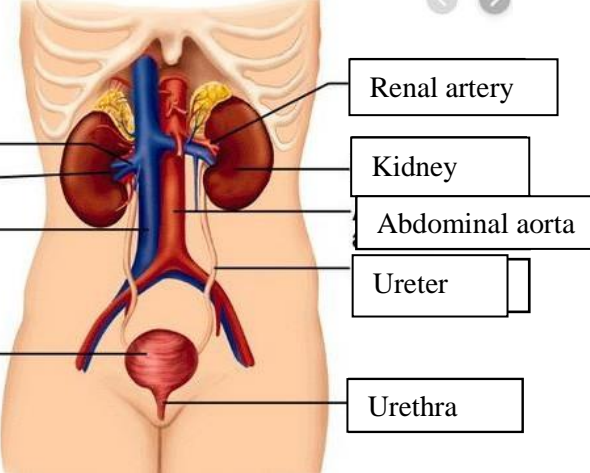
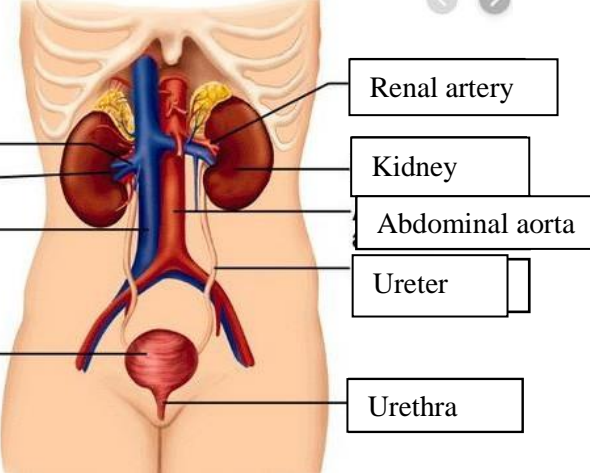
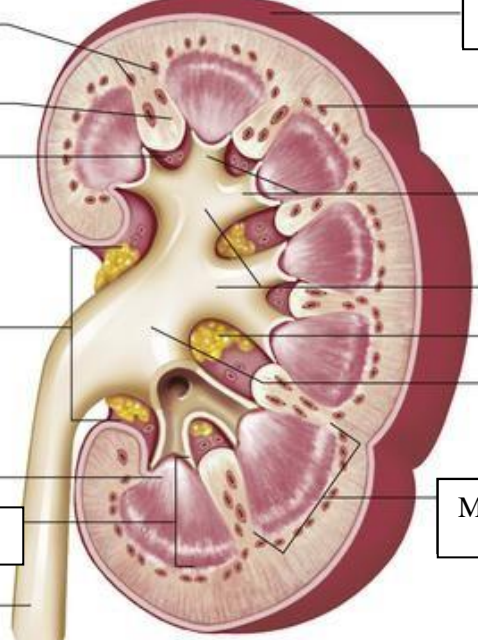


Mata Kuliah	: Anatomi
Materi	: Anatomi Urinari
NIM>Nama Mahasiswa	: 2110101103/ALFINA FEBRIYANI

No	Keterangan	Pembahasan
1	<p>Urinary System</p>  <p>Renal vein</p> <p>Hilum</p> <p>Inferior vena cava</p> <p>Urinary bladder</p>	 <p>Renal artery</p> <p>Kidney</p> <p>Abdominal aorta</p> <p>Ureter</p> <p>Urethra</p>
	<p>Cortical blood vessels</p> <p>Renal column</p> <p>Papilla medulla</p> <p>Pelvis renal</p> <p>Kaliks minor</p> <p>Pyramid renal dalam medulla renal</p> <p>Ureter</p>	 <p>Kapsul fibrous</p> <p>Cortical blood vessels</p> <p>Minor cylox</p> <p>Major calyx</p> <p>Lemak dalam sinus renal</p> <p>Renal pelvis</p> <p>Medulla</p>