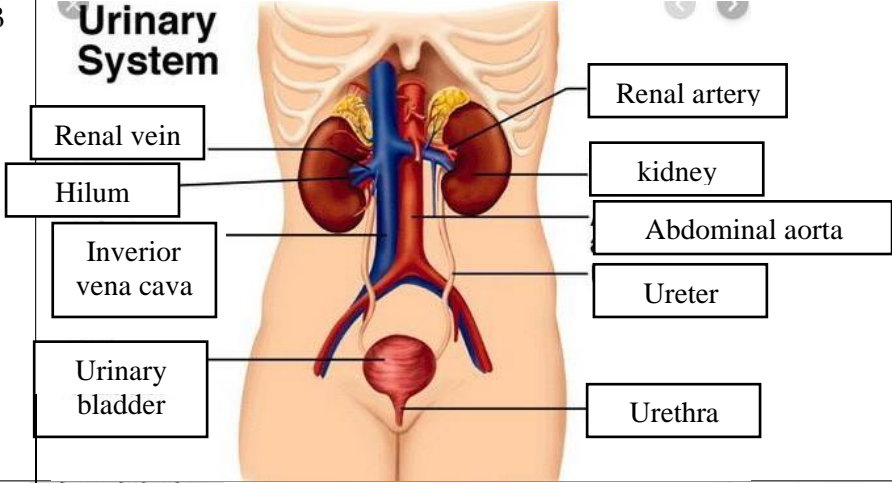
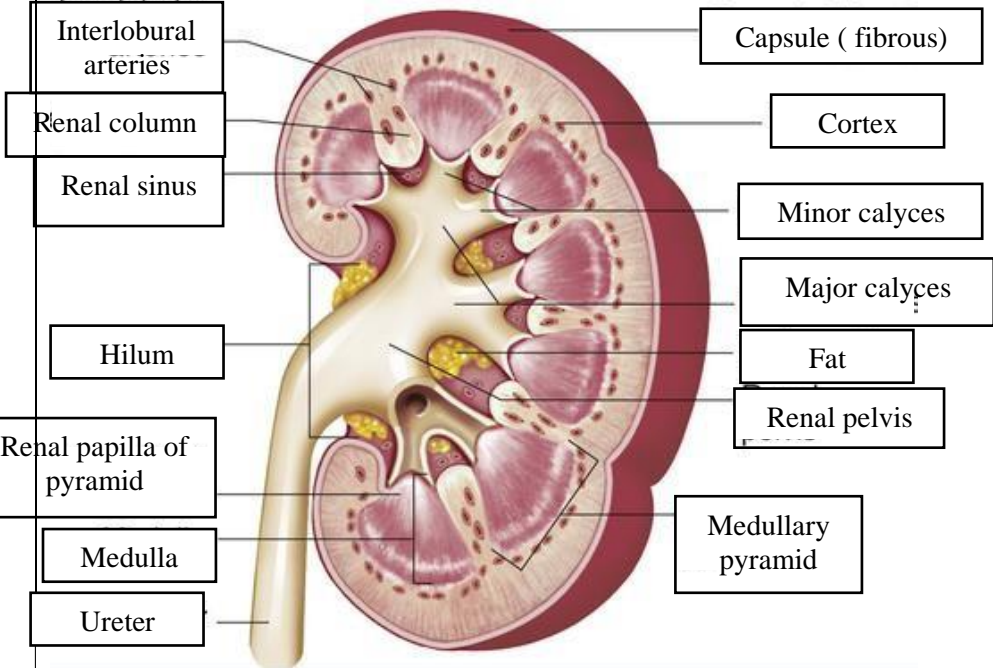


**WORKSHEETS (LEMBAR KERJA)**

<b>Mata Kuliah</b>	: <b>Anatomi</b>
<b>Materi</b>	: <b>Anatomi Urinari</b>
<b>NIM&gt;Nama Mahasiswa</b>	: <b>2110101105/Shivani Nurrahmah Purnady</b>

No	Keterangan	Pembahasan
<p>33</p> <p><b>Urinary System</b></p>  <p>Renal vein</p> <p>Hilum</p> <p>Inferior vena cava</p> <p>Urinary bladder</p> <p>Renal artery</p> <p>kidney</p> <p>Abdominal aorta</p> <p>Ureter</p> <p>Urethra</p>		
	 <p>Interlobular arteries</p> <p>Renal column</p> <p>Renal sinus</p> <p>Hilum</p> <p>Renal papilla of pyramid</p> <p>Medulla</p> <p>Ureter</p> <p>Capsule ( fibrous)</p> <p>Cortex</p> <p>Minor calyces</p> <p>Major calyces</p> <p>Fat</p> <p>Renal pelvis</p> <p>Medullary pyramid</p>	