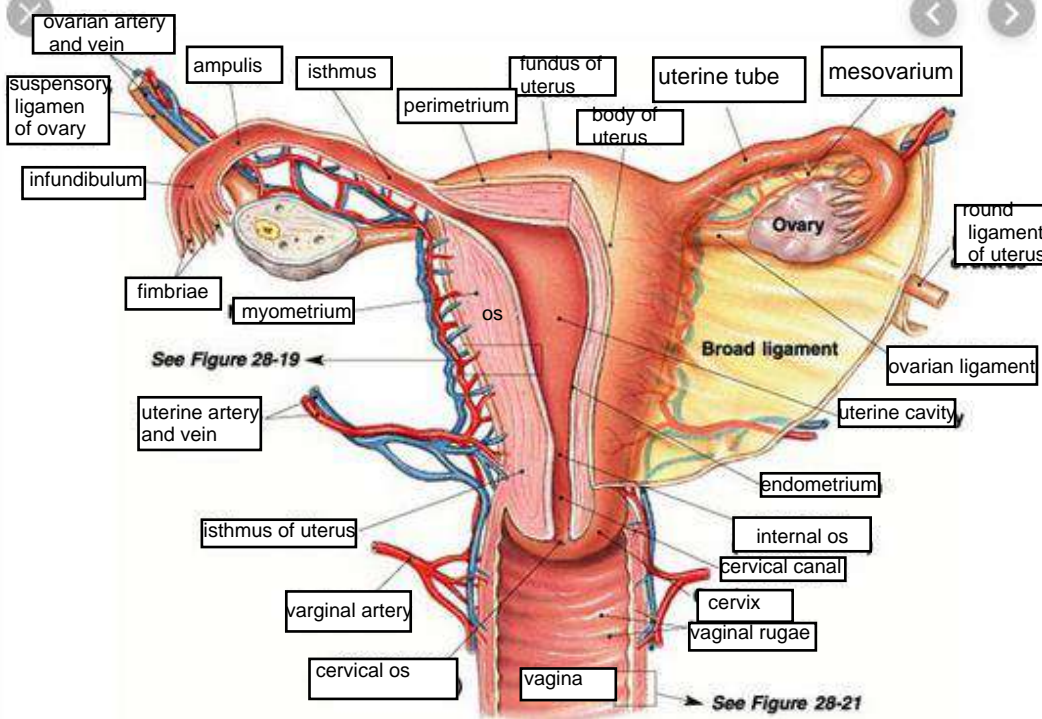
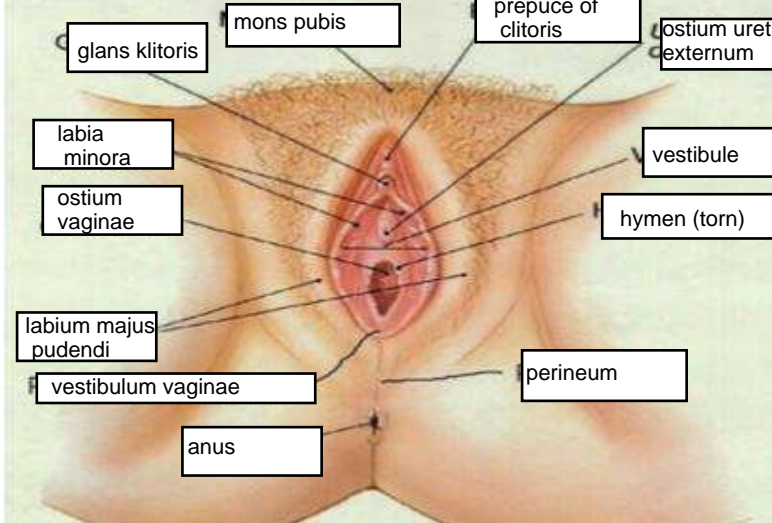
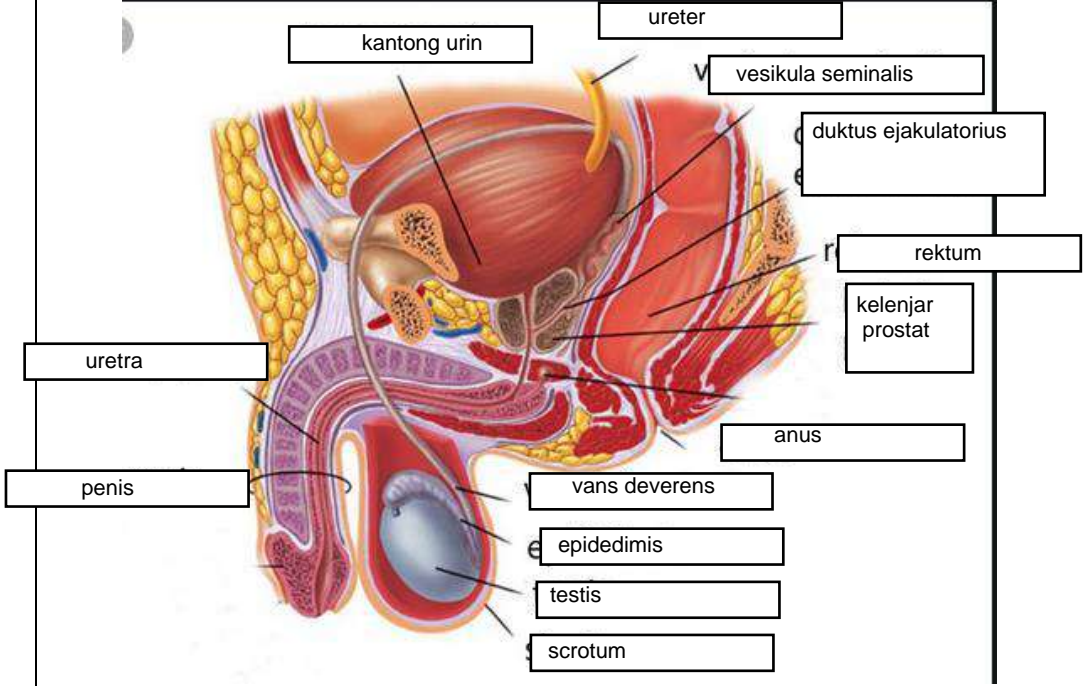
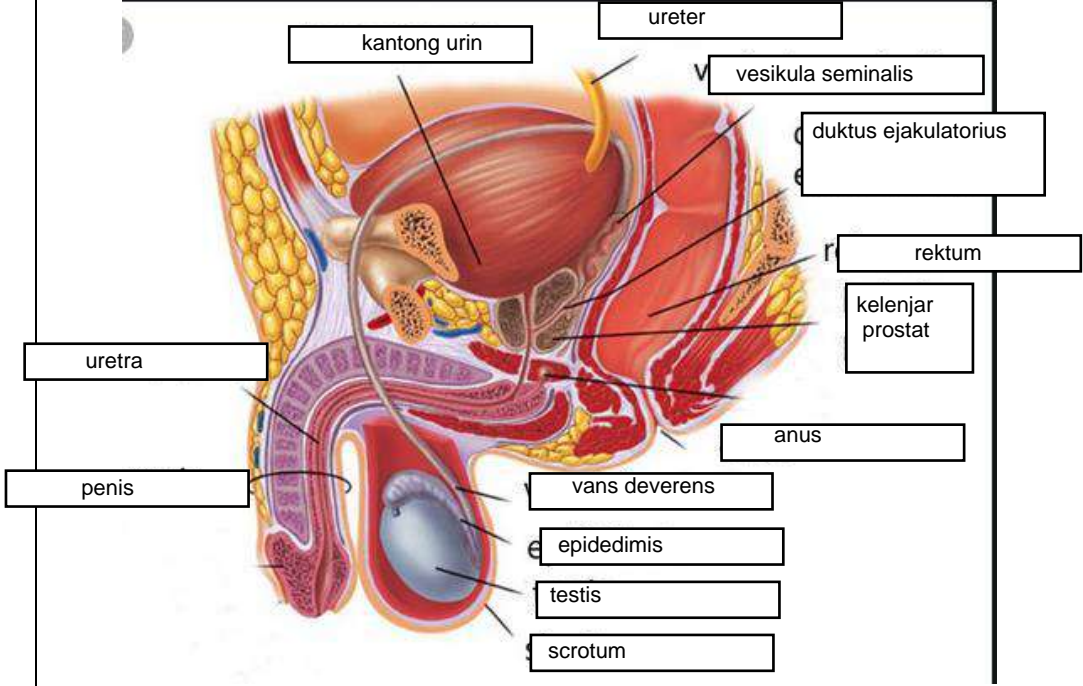
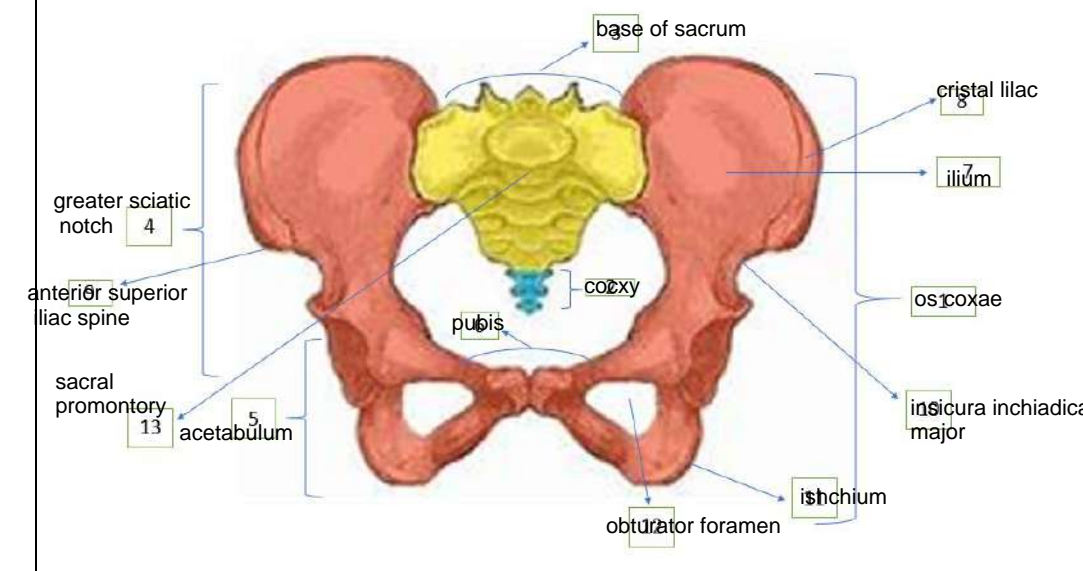
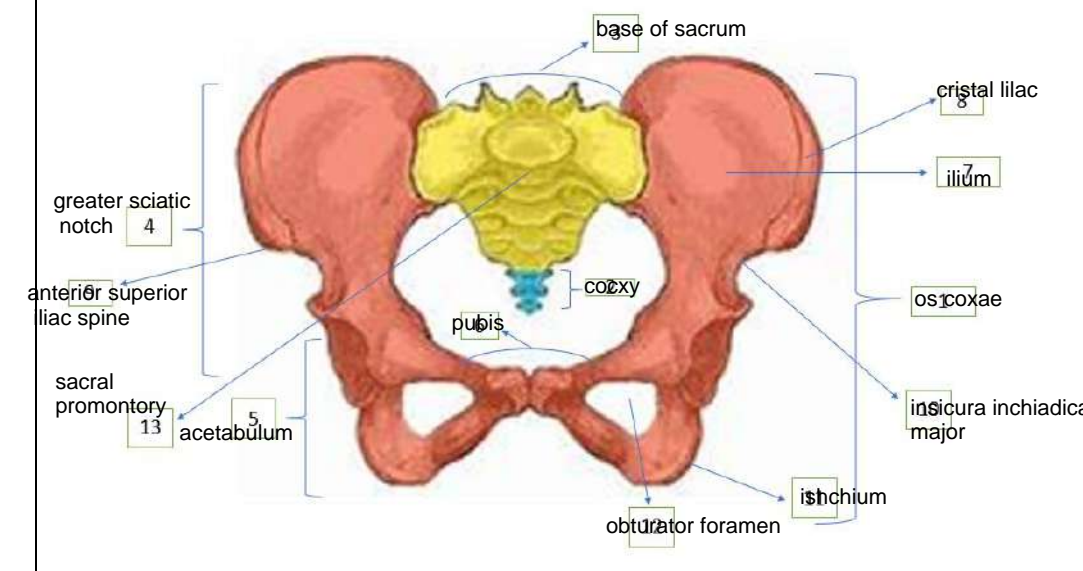
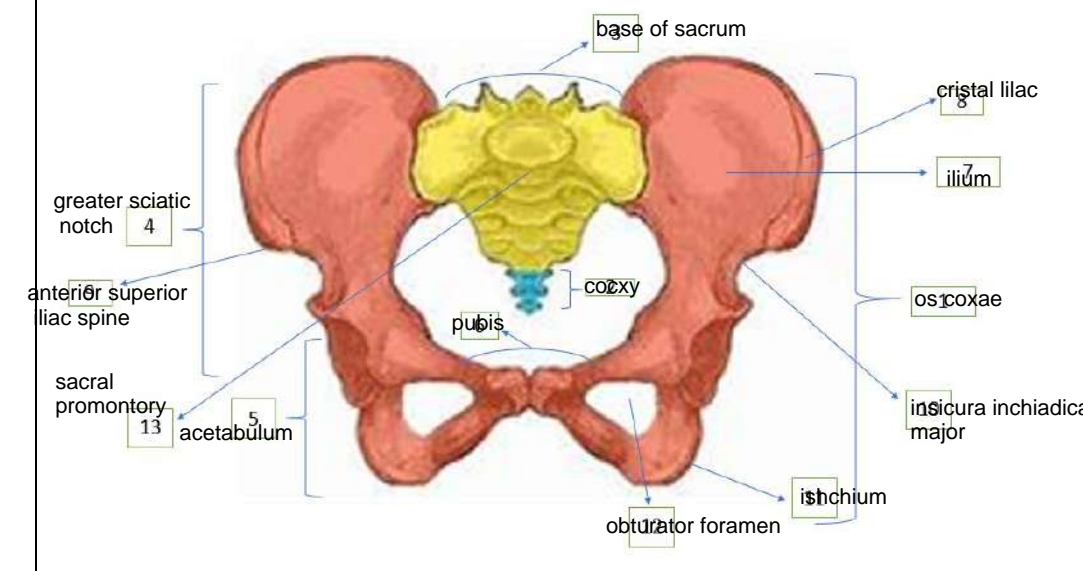
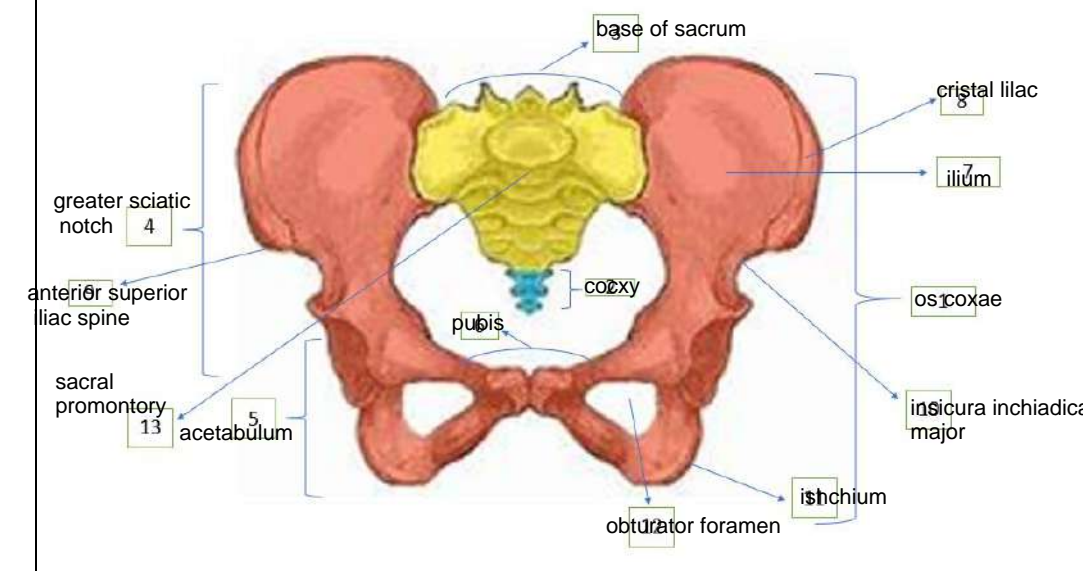


WORKSHEETS (LEMBAR KERJA)

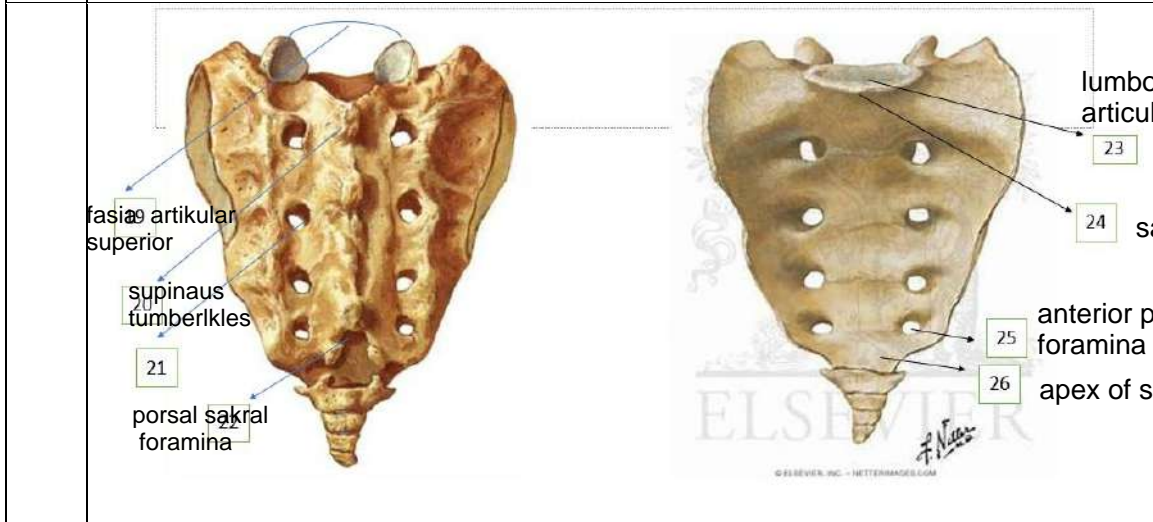
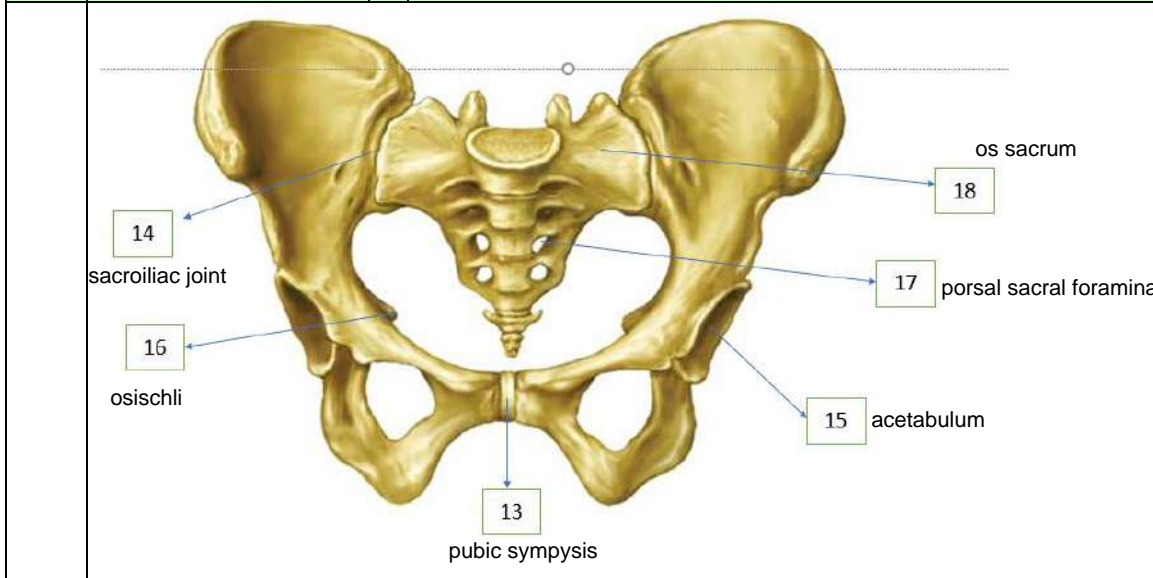
Mata Kuliah	: Anatomi
Materi	: Anatomi Reproduksi
NIM>Nama Mahasiswa	: Izza syifa wahyu / 2110101032

No	Keterangan	Pembahasan
1		 <p>This diagram illustrates the female reproductive system. Key internal structures labeled include the fundus of uterus, body of uterus, isthmus, perimetrium, myometrium, endometrium, uterine tube, uterine cavity, internal os, cervical canal, cervix, and vagina. The diagram also shows the uterine artery and vein, ovarian artery and vein, suspensory ligament of ovary, infundibulum, fimbriae, mesovarium, broad ligament, ovarian ligament, and round ligament of uterus. External structures shown include the vaginal os, vaginal rugae, and the vulva. A reference to 'See Figure 28-19' and 'See Figure 28-21' is included.</p>
		 <p>This diagram shows the external female genitalia (vulva). Labeled parts include the mons pubis, glans klitoris, prepuce of clitoris, ostium urethrae externum, labia minora, labium majus pudendi, ostium vaginae, vestibule, hymen (torn), vestibulum vaginae, perineum, and anus.</p>

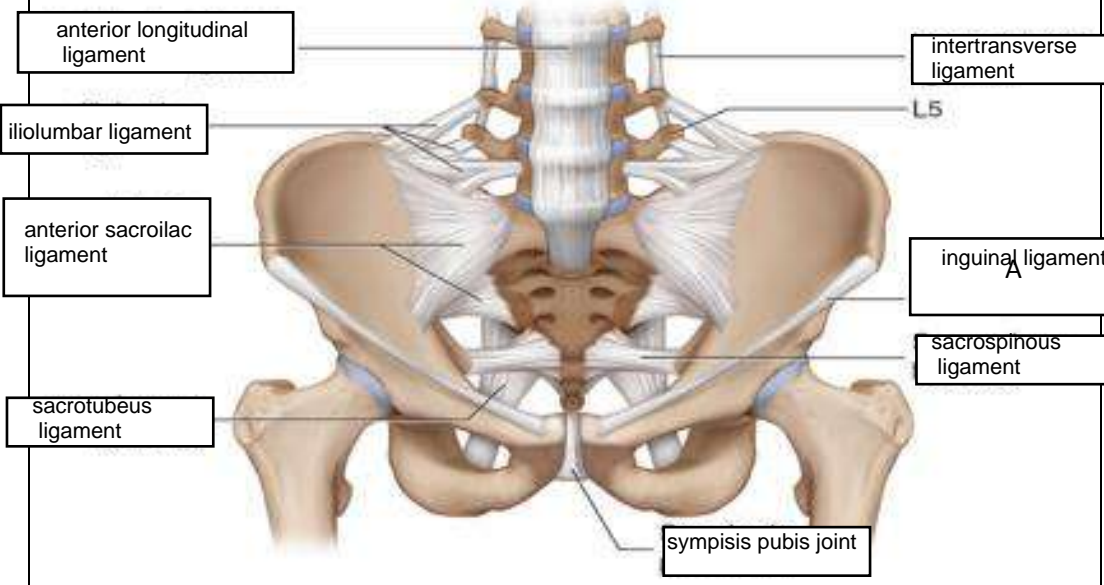
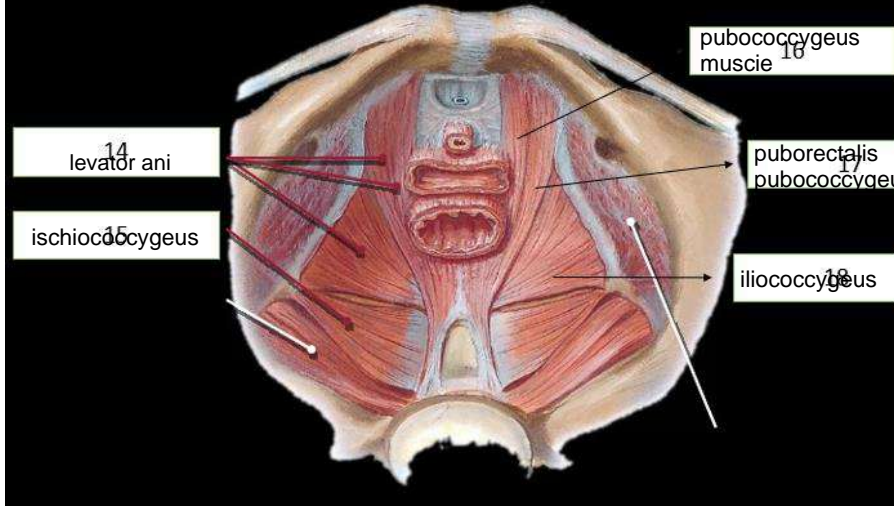
No	Keterangan	Pembahasan
		
		

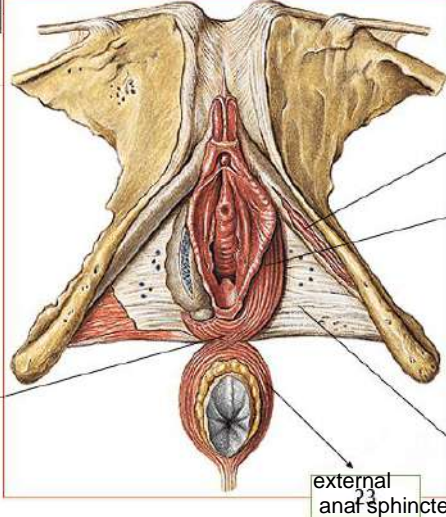
		
--	---	---

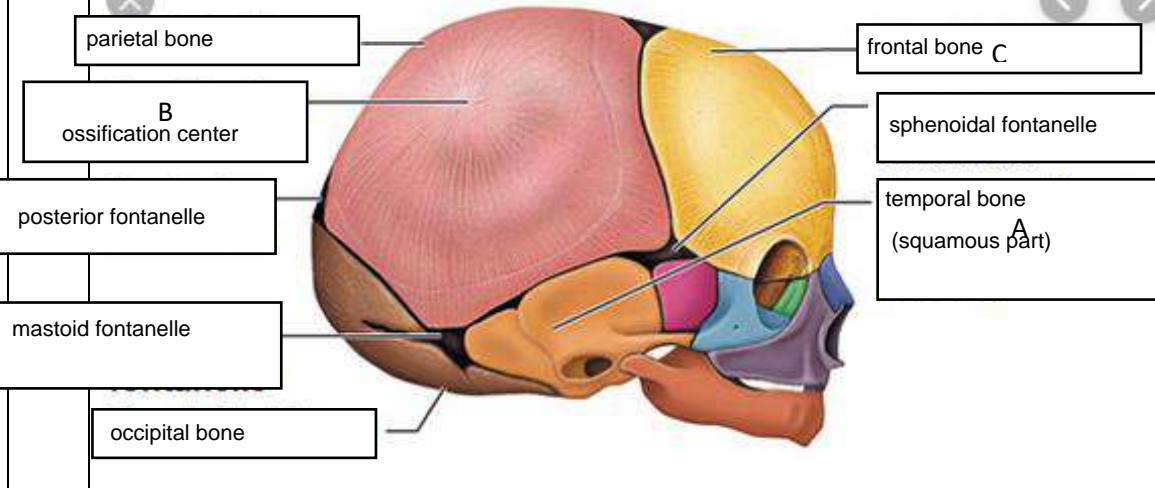
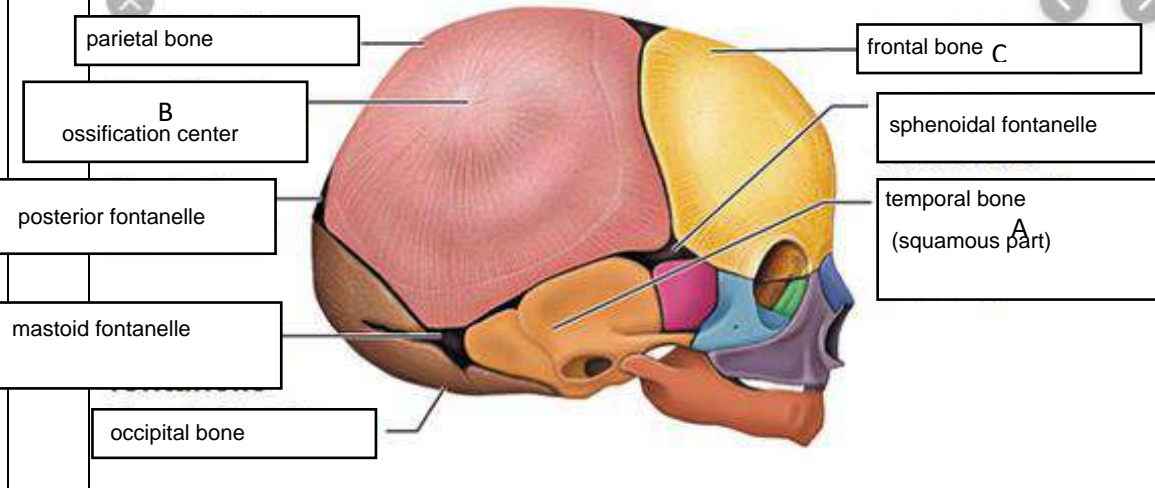
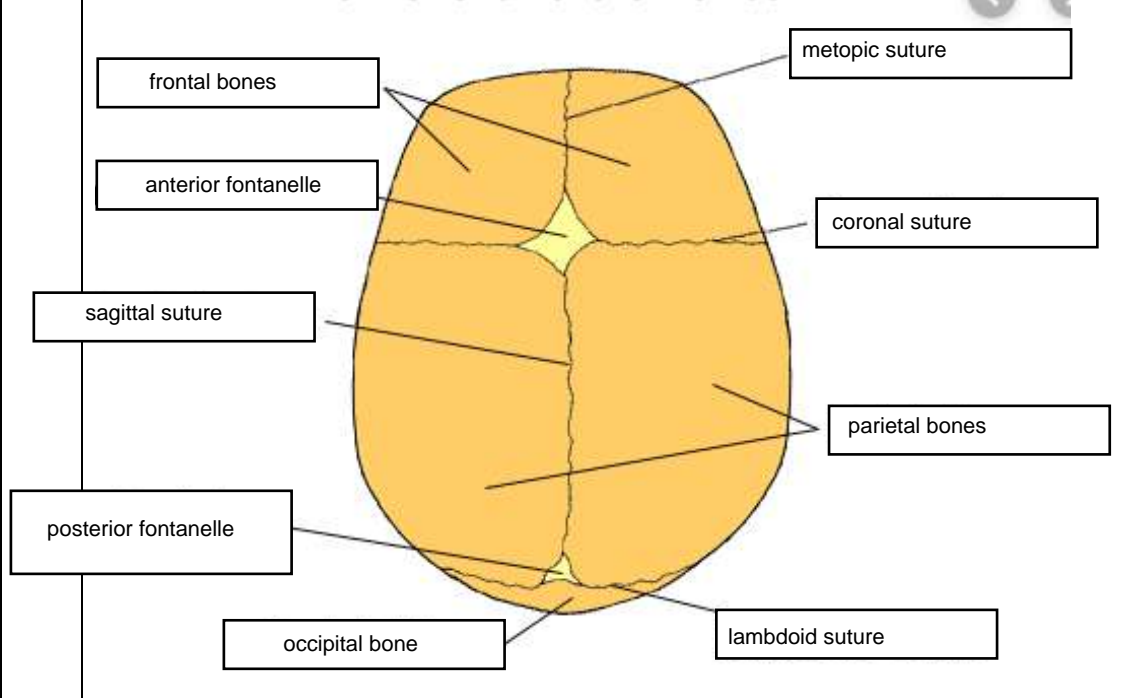
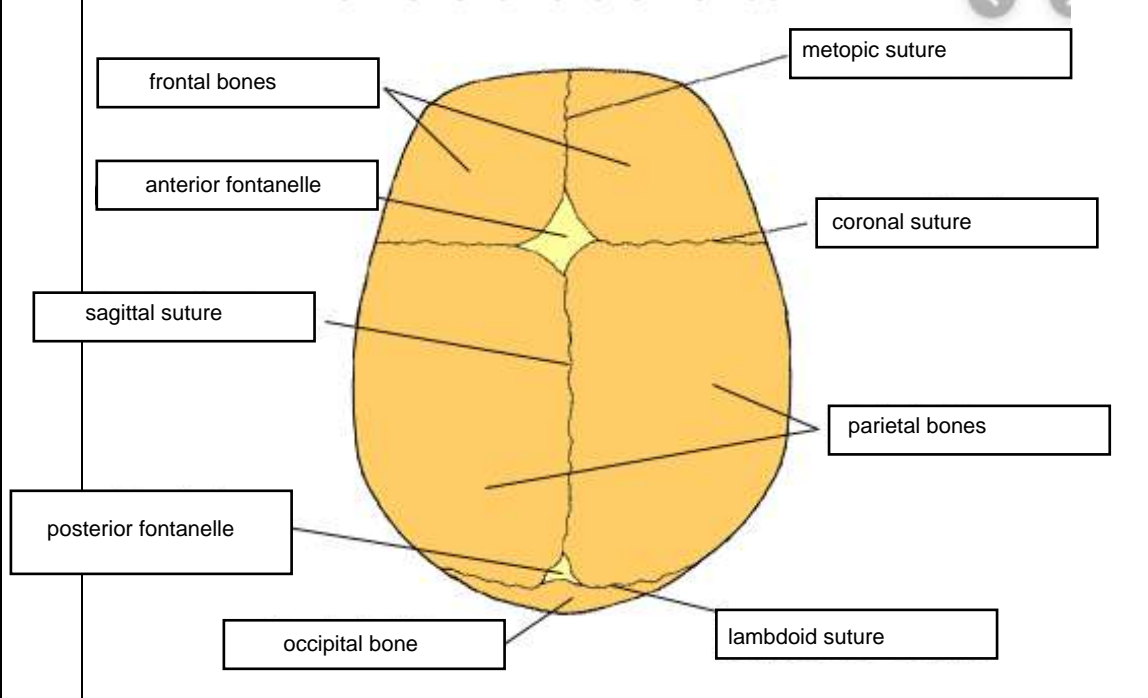
No	Keterangan	Pembahasan
----	------------	------------



• **Persendian pada pelvis** sacrococcygeal joint, (27), symphysis pubis.....(28), sacroiliac kanan dan kiri (29)

No	Keterangan	Pembahasan
		
		
	<p>Jelaskan jenis panggul</p>	<ol style="list-style-type: none"> 1. jenis gynaecoid bentuk hampir mirip lingkaran diameter anteroposterior kira kira sama dengan diameter transversa ditemukan 45 persen wanita 2. jenis anthropoid bentuk elips membujur anteroposterior diameter anteroposterior lebih besar dari diameter transversa jenis ini ditemukan pada 35 persen wanita 3. jenis android bentuk hampir segitiga belakan ditemukan pada 15 persen wanita jenis panggul tipikal pria 4. jenis platypeloid jenis ginekoid yang menyempit pada arah muka ditemukan pada 5 persen wanita

No	Keterangan	Pembahasan
	<p>Click to ad</p>	 <p>ischio-cavernosus muscle</p> <p>bulbospongiosus muscle</p> <p>perineal body</p> <p>external anal sphincter</p> <p>inferior fascia of urogenital diaphragm</p>
	<p>Sebutkan ukuran panggul dalam</p>	<p>Conjugata vera anatomica..... jarak antara promontorium ke tepi cranial symphysis pubis</p> <p>Conjugata vera obstetrika..... jarak antara promontorium ke dinding dorsal symphysis pubis 106 cm</p> <p>Conjugata diagonalis..... jarak antara promontorium ke tepi caudal symphysis pubis diukur dengan vt memperkirakan conjugata vera 12,5 cm</p> <p>Diameter transversa..... jarak terbesar antara linea arcuate /linea terminalis ka-ki (12,5 – 13 cm)</p> <p>Diameter obliqua..... Diameter obliqua : artikulasio sacroiliaca ke titik persekutuan antara diameter transversa dan conjugata vera dan diteruskan ke linea inominata (± 12,5 cm)</p>
	<p>Ukuran panggul luar</p>	<p>Conjugata boudelogeu..... tepi cranial simp – proc spinosus VL V (18 – 20 cm)</p> <p>Distansia spinarum..... jarak kedua spina iliaca anterior superior (23 -26 cm)</p> <p>Distansia cristarum..... jarak kedua crista iliaca (26 – 29 cm)</p> <p>Distansia tuberum..... jarak antara kedua tuberi schiadicum (10,5 – 11)</p>

No	Keterangan	Pembahasan
	 <p>parietal bone</p> <p>B ossification center</p> <p>posterior fontanelle</p> <p>mastoid fontanelle</p> <p>occipital bone</p>	 <p>frontal bone C</p> <p>sphenoidal fontanelle</p> <p>temporal bone (squamous part) A</p>
	 <p>frontal bones</p> <p>anterior fontanelle</p> <p>sagittal suture</p> <p>posterior fontanelle</p> <p>occipital bone</p>	 <p>metopic suture</p> <p>coronal suture</p> <p>parietal bones</p> <p>lambdoid suture</p>
	<p>Jelaskan bidang hodge</p> <p>: Bidang untuk menentukan seberapa jauh penurunan bagian janin ke dalam cavum pelvis</p>	