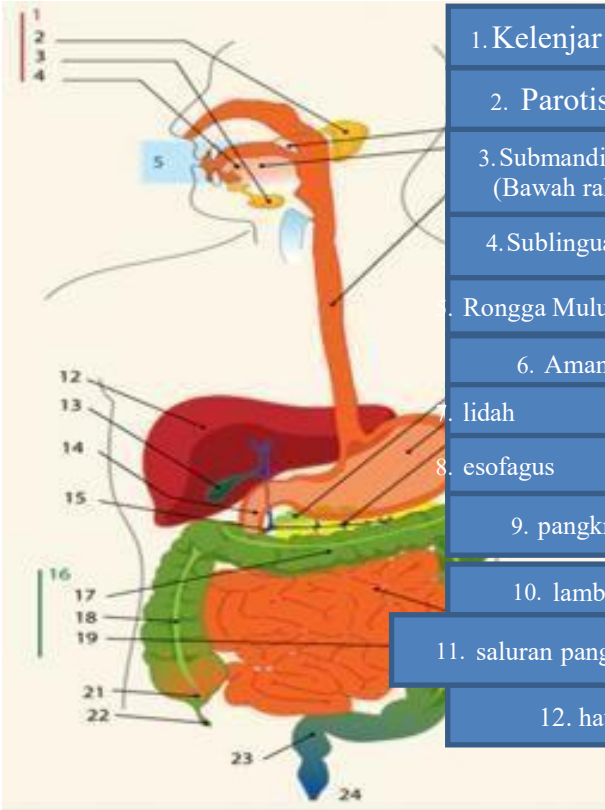
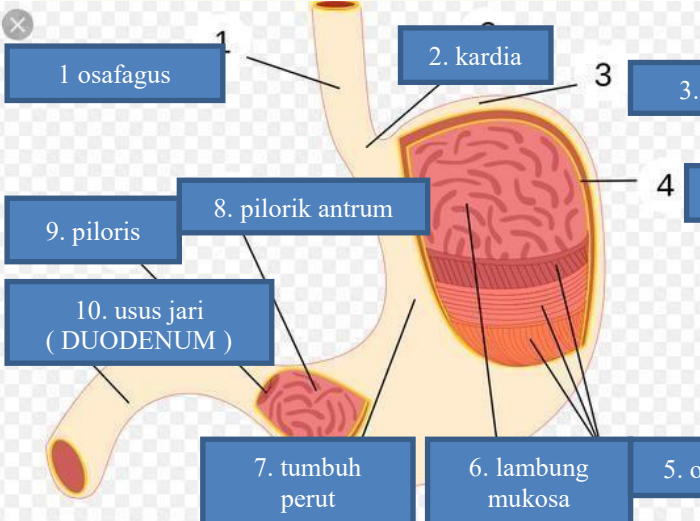
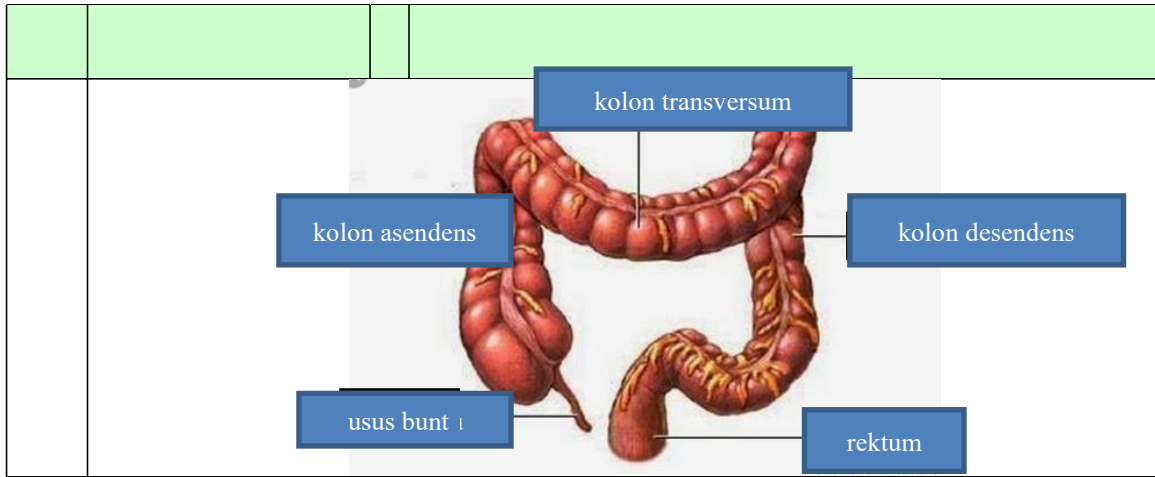


WORKSHEETS (LEMBAR KERJA)

Mata Kuliah	: Anatomi
Materi	: Anatomi Digesti
NIM>Nama Mahasiswa	: 2110101028 LEDY SUPRIHATIN

Keterangan	Pembahasan																										
	<table border="1"> <tr><td>1. Kelenjar</td><td></td></tr> <tr><td>2. Parotis</td><td>13. kantong empedu</td></tr> <tr><td>3. Submandibularis (Bawah rahang)</td><td>14. duodenum</td></tr> <tr><td>4. Sublingualis (bawah)</td><td>15. saluran empedu</td></tr> <tr><td>5. Rongga Mulut</td><td>16. kolon</td></tr> <tr><td>6. Amandel</td><td>17. kolon transversum</td></tr> <tr><td>7. lidah</td><td>18. kolon acenden</td></tr> <tr><td>8. esofagus</td><td>19. kolon descendun</td></tr> <tr><td>9. pankreas</td><td>20. ileum</td></tr> <tr><td>10. lambung</td><td>21. sekum</td></tr> <tr><td>11. saluran pankreas</td><td>22. appendiks/poros usus</td></tr> <tr><td>12. hati</td><td>23. rectum/poros usus</td></tr> <tr><td></td><td>24. anus</td></tr> </table>	1. Kelenjar		2. Parotis	13. kantong empedu	3. Submandibularis (Bawah rahang)	14. duodenum	4. Sublingualis (bawah)	15. saluran empedu	5. Rongga Mulut	16. kolon	6. Amandel	17. kolon transversum	7. lidah	18. kolon acenden	8. esofagus	19. kolon descendun	9. pankreas	20. ileum	10. lambung	21. sekum	11. saluran pankreas	22. appendiks/poros usus	12. hati	23. rectum/poros usus		24. anus
1. Kelenjar																											
2. Parotis	13. kantong empedu																										
3. Submandibularis (Bawah rahang)	14. duodenum																										
4. Sublingualis (bawah)	15. saluran empedu																										
5. Rongga Mulut	16. kolon																										
6. Amandel	17. kolon transversum																										
7. lidah	18. kolon acenden																										
8. esofagus	19. kolon descendun																										
9. pankreas	20. ileum																										
10. lambung	21. sekum																										
11. saluran pankreas	22. appendiks/poros usus																										
12. hati	23. rectum/poros usus																										
	24. anus																										
	<table border="1"> <tr><td>1. osafagus</td><td>2. kardia</td><td>3. fundus</td></tr> <tr><td>4. selaput</td><td>5. otot lapisan</td><td>6. lambung mukosa</td></tr> <tr><td>7. tumbuh perut</td><td>8. pilorik antrum</td><td>9. piloris</td></tr> <tr><td>10. usus jari (DUODENUM)</td><td></td><td></td></tr> </table>	1. osafagus	2. kardia	3. fundus	4. selaput	5. otot lapisan	6. lambung mukosa	7. tumbuh perut	8. pilorik antrum	9. piloris	10. usus jari (DUODENUM)																
1. osafagus	2. kardia	3. fundus																									
4. selaput	5. otot lapisan	6. lambung mukosa																									
7. tumbuh perut	8. pilorik antrum	9. piloris																									
10. usus jari (DUODENUM)																											



No

Keterangan

Pembahasan