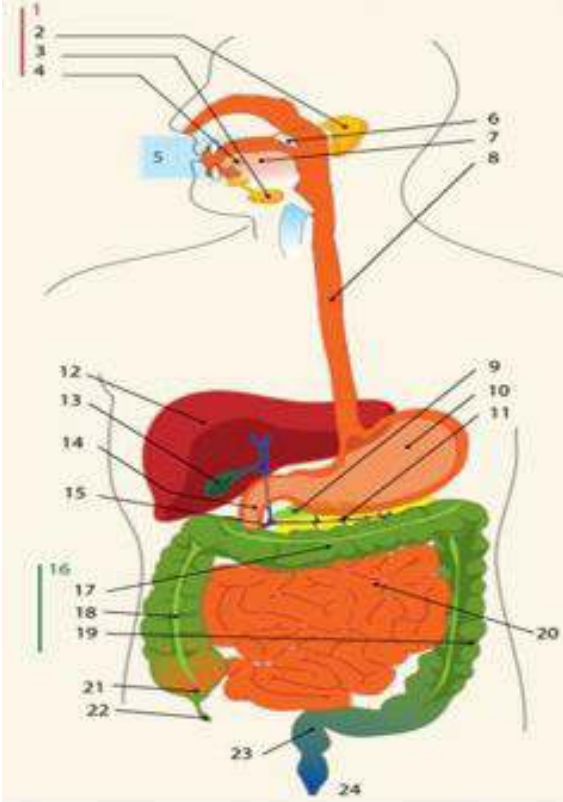
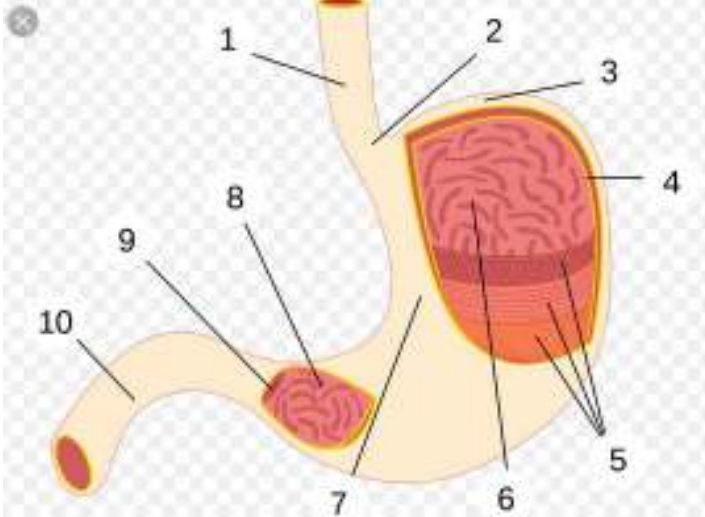
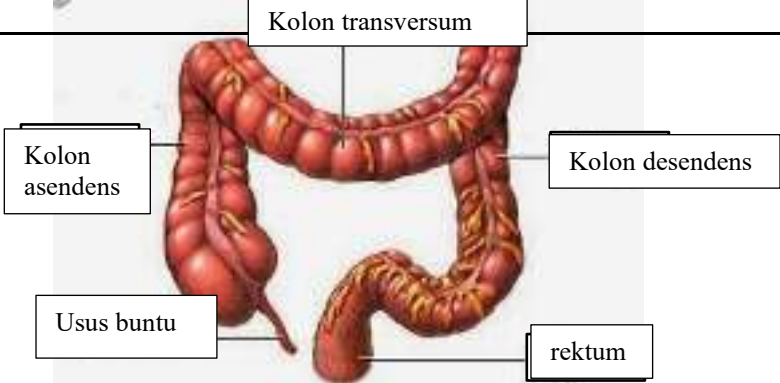


WORKSHEETS (LEMBAR KERJA)

Mata Kuliah	: Anatomi
Materi	: Anatomi Digesti
NIM>Nama Mahasiswa	: 2110101054/Nur Annisa Ahla

No	Keterangan	Pembahasan
1		<ol style="list-style-type: none"> 1.kelenjar 2.parotis 3.submandibularis 4.sublingualis 5.rongga mulut 6.amandel 7.lidah 8.esofagus 9.pankreas 10.lambung 11.saluran pankreas 12.hati 13.kantung empedu 14.duodenum 15.saluran empedu 16.kolon 17.kolon transversum 18.kolom aacenden 19.kolon descendun 20.ileum 21.sekum 22.appendiks/poros usus 23.rektum poros usus 24.anus
		<ol style="list-style-type: none"> 1.osafagus 2.kardia 3.fundus 4.selaput lender 5.otot lapisan 6.lambung mukosa 7.tumbuh perut 8.piloric antrum 9.piloris 10.usus jari

No	Keterangan	Pembahasan
		 <p>The diagram illustrates the large intestine (colon) and its associated structures. The main components are labeled as follows:</p> <ul style="list-style-type: none"> Kolon transversum: The transverse colon, which is the upper horizontal part of the large intestine. Kolon asendens: The ascending colon, the vertical part on the right side of the abdomen. Usus buntu: The vermiform appendix, a small finger-like projection from the junction of the ascending and transverse colons. Kolon desendens: The descending colon, the vertical part on the left side of the abdomen. rektum: The rectum, the final straight part of the large intestine that leads to the anus.