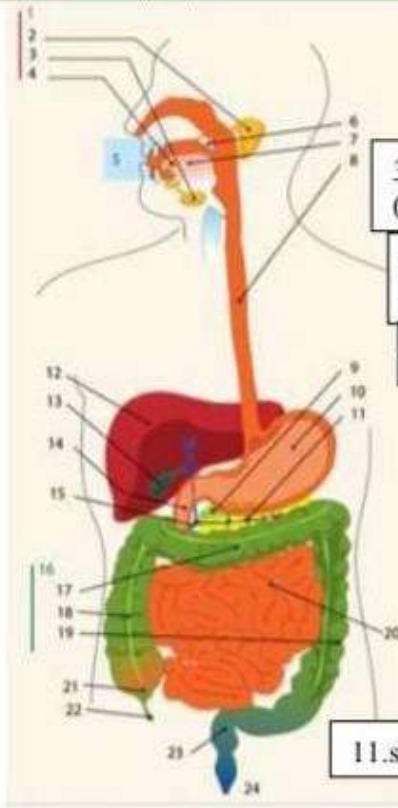


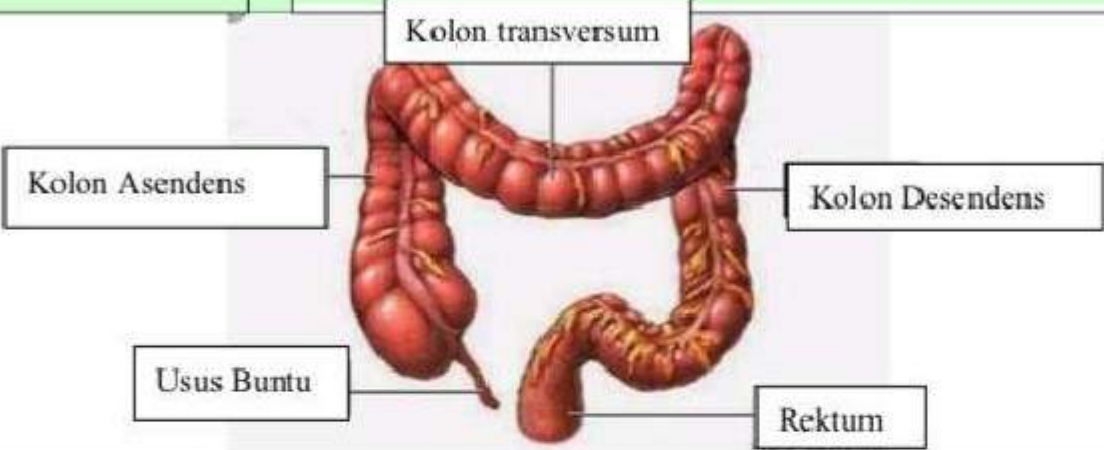
WORKSHEETS LEMBARKERJA

Mata Kuliah	Anatomi
Materi	Anatomi Digesti
N 1M>Nama Mahasiswa	2110101045 / Nadia Putri Anggraheni

No	Keterangan	Pembahasan
----	------------	------------

1		1.kelenjar	13.kantung empedu
		2.parotis	14.duodenum
		3.submandibularis (bawah rahang)	15.saluran empedu
		4.sublingualis (bawah lidah)	16.kolon
		5.rongga mulut	17.kolon transversum
		6.amandel	18.kolon aacenden
		7.lidah	19.kolon descendun
		8.esofagus	20.ileum
		9.pankreas	21.sekum
		10.lambung	22.appendiks/poros usus
		11.saluran pankreas	23.rektum/poros usus
		12.hati	24.anus

1.osafagus	2.kardia	3.fundus
8.piloric antrum	4.selaput lender	
9.piloris	5.otot lapisan	
10.usus jari (duodenum)	6.lambung mukosa	
7.tumbuh perut		

No	Keterangan	Pembahasan
		 <p>The diagram illustrates the large intestine (colon) and its associated structures. The main components are labeled as follows:</p> <ul style="list-style-type: none"> Kolon transversum: The upper horizontal part of the large intestine. Kolon Asendens: The vertical part of the large intestine on the right side. Usus Buntu: The vermiform appendix, a small finger-like projection from the cecum. Kolon Desendens: The vertical part of the large intestine on the left side. Rektum: The final straight part of the large intestine, leading to the rectum.