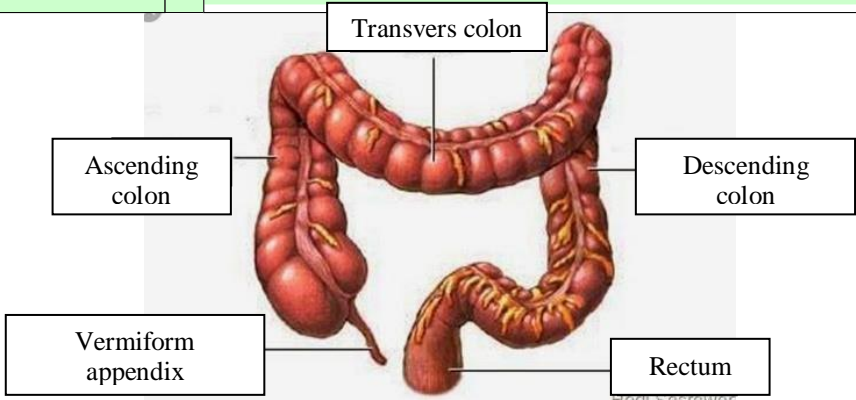


WORKSHEETS (LEMBAR KERJA)

Mata Kuliah	: Anatomi
Materi	: Anatomi Digesti
NIM>Nama Mahasiswa	: 2110101048/Azahra Andini Putri

No	Keterangan	Pembahasan
	1. salivari glands	
2. Parotid		6. soft palate
3. Sublingual		7. tongue
4. submandibular		8. Esophagus
5. oral cavity		
12. Liver		9. pancreas
13. Gallbladder		10. Stomach
14. Duodenum		11. pancreatic duct
15. common bile duct		
17. transvers colon		Small intestine
18. taenia coli		
19. sigmoid colon		
21. cecum		
22. Appendix		
16. usus besar		
	Rectum	24. Anus

Esophagus	Cardia	Fundus	Serosa
Pyloric antrum			
Pyloric sphincter			
Duodenum			
Body	Rugae	Layer mucle	

No	Keterangan	Pembahasan
		 <p>The diagram illustrates the large intestine (colon) and its associated structures. The main components are labeled as follows:</p> <ul style="list-style-type: none"> Ascending colon: The upper right portion of the large intestine. Transvers colon: The horizontal upper portion of the large intestine. Descending colon: The lower right portion of the large intestine. Vermiform appendix: A small, finger-like projection from the junction of the ascending and transverse colons. Rectum: The terminal part of the large intestine, leading to the anus. <p><small>Hedi Sasrawar</small></p>