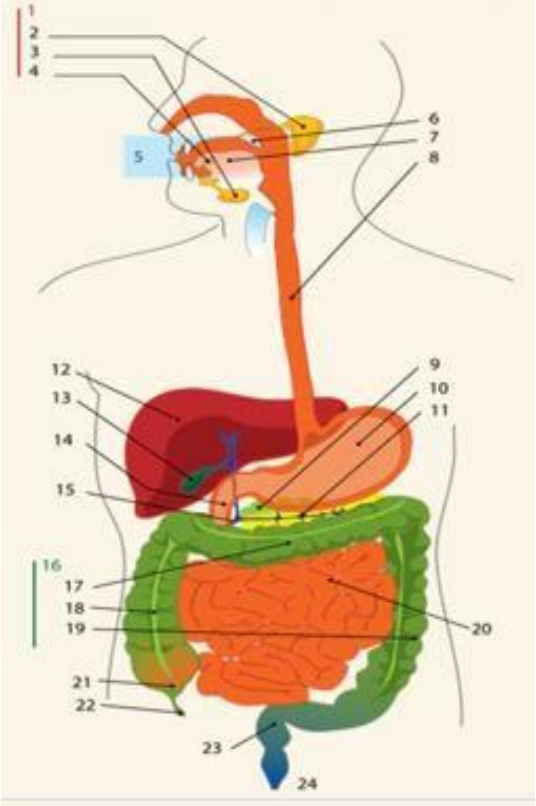
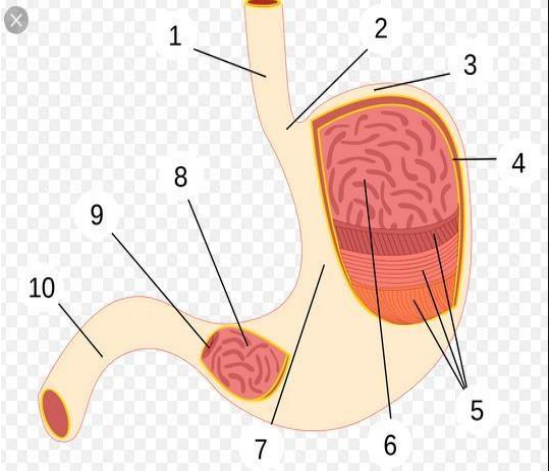
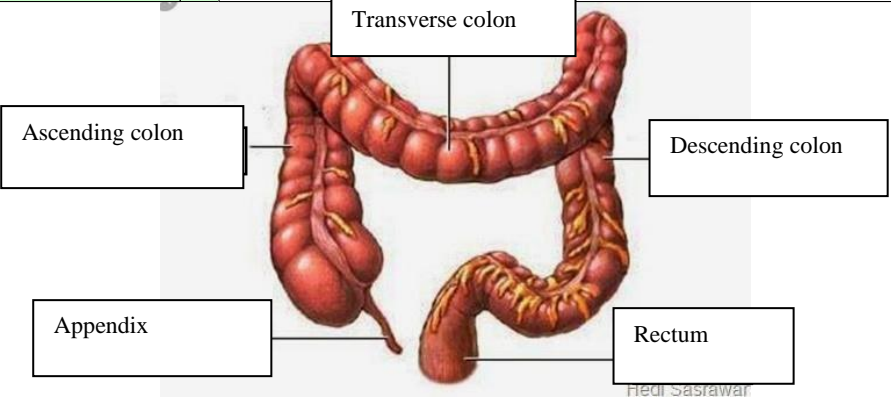


WORKSHEETS (LEMBAR KERJA)

Mata Kuliah	: Anatomi
Materi	: Anatomi Digesti
NIM>Nama Mahasiswa	: 2110101025/Afifah Rosiana

No	Keterangan	Pembahasan
1		<ol style="list-style-type: none"> 1. Kelenjar ludah 2. Parotis 3. Submandibularis (bawah rahang) 4. Sublingualis (bawah lidah) 5. Rongga mulut 6. Amandel 7. Lidah 8. Esofagus 9. Pancreas 10. Lambung 11. Saluran pancreas 12. Hati 13. Kantong empedu 14. Duodenum 15. Saluran empedu 16. Kolon 17. Kolon transversum 18. Kolon ascenden 19. Kolon descenden 20. Ileum 21. Sekum 22. Appendiks 23. Rectum 24. Anus
		<ol style="list-style-type: none"> 1. Esofagus 2. Kardia 3. Fundus 4. Selaput lender 5. Otot lapisan 6. Lambung mukosa 7. Tubuh perut 8. Pilorik antrum 9. Pylorus 10. Duodenum

No	Keterangan	Pembahasan
		 <p>The diagram illustrates the large intestine (colon) and its associated structures. The main components are labeled as follows:</p> <ul style="list-style-type: none"> Transverse colon: The upper horizontal part of the large intestine. Ascending colon: The vertical part on the right side of the abdomen. Descending colon: The vertical part on the left side of the abdomen. Appendix: A small, finger-like projection from the bottom of the cecum (the junction where the ascending colon meets the transverse colon). Rectum: The final straight part of the large intestine, leading to the anus. <p><small>Hedi Sasrawar</small></p>