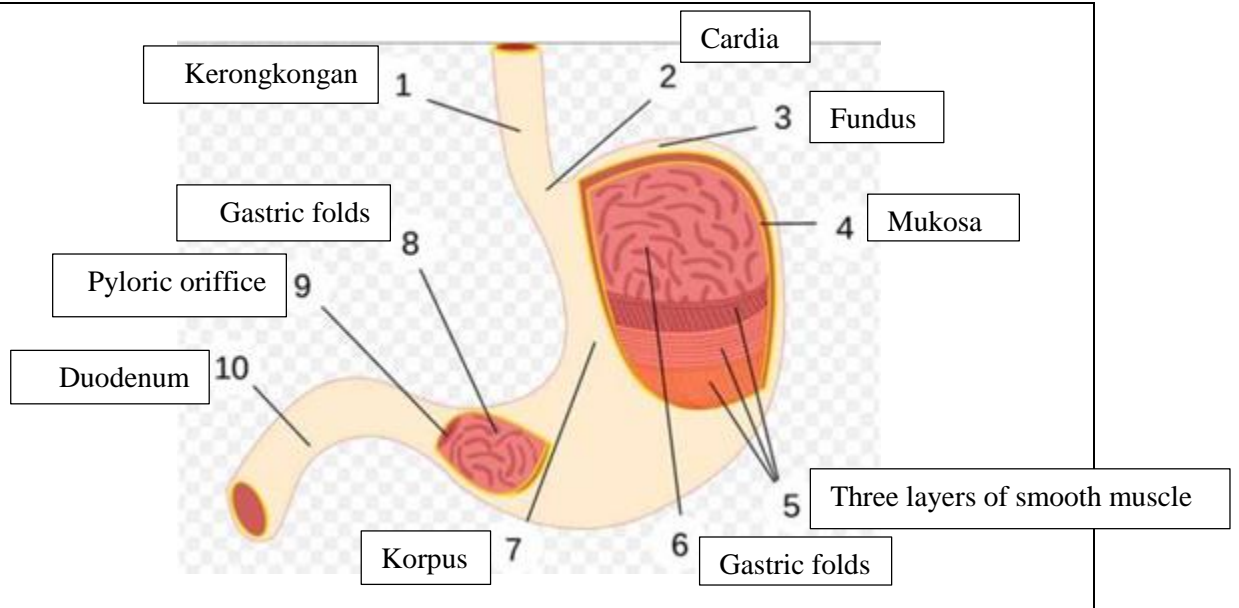


WORKSHEETS (LEMBAR KERJA)

Mata Kuliah	Anatomi
Materi	Anatomi Digesti
NIM>Nama Mahasiswa	2110101023 / Amalia Zidny

No	Keterangan	Pembahasan
1	<p>2. Parotis</p> <p>3. Submandibularis</p> <p>4. Sublingualis</p> <p>5. Rongga mulut</p> <p>6. Amandel</p> <p>7. Lidah</p> <p>8. Esofagus</p> <p>9. Pankreas</p> <p>10. Lambung</p> <p>11. Saluran pankreas</p> <p>12. Hati</p> <p>13. Kantung empedu</p> <p>14. Duodenum</p> <p>15. Saluran empedu</p> <p>16. Kolon</p> <p>17. Kolon transversum</p> <p>18. Kolon ascenden</p> <p>19. Kolon desenden</p> <p>20. Ileum</p> <p>21. Sekum</p> <p>22. Appendiks/umbai cacing</p> <p>23. Rektum/poros usus</p> <p>24. Anus</p>	

2



No	Keterangan	Pembahasan
3		<p>An anatomical diagram of the large intestine (colon) in a frontal view. The diagram is labeled with the following parts: Transversum (Transverse colon), Kolon asenden (Ascending colon), Kolon desenden (Descending colon), Usus buntu (Cecum), and Rektum (Rectum). The diagram shows the characteristic S-shaped curve of the large intestine.</p>