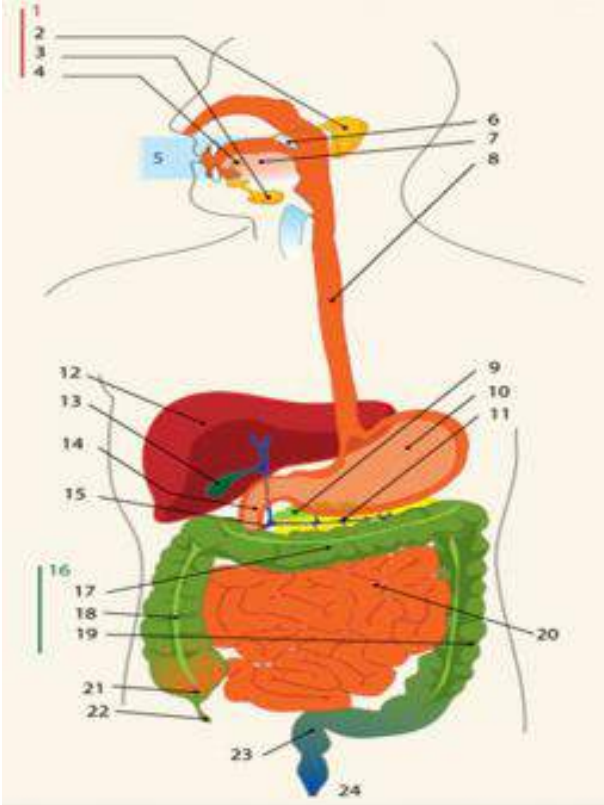
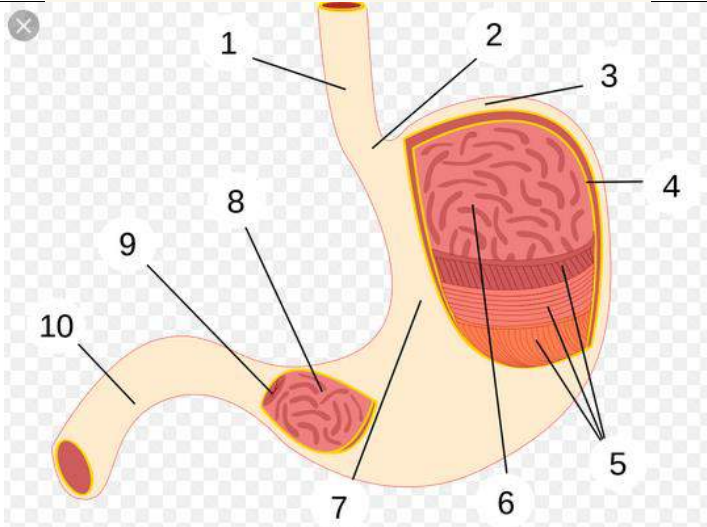
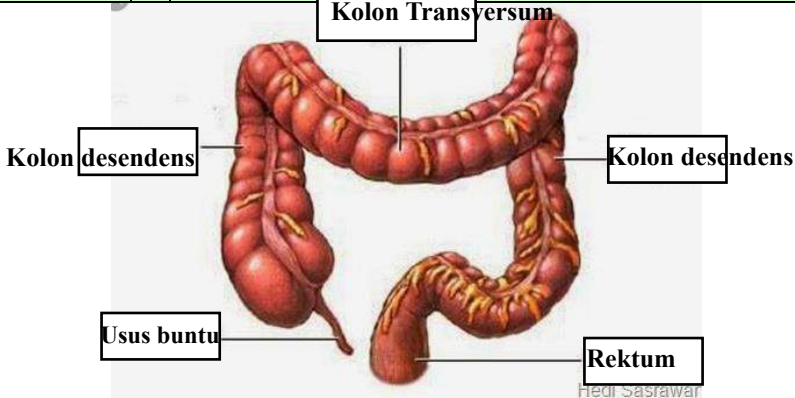


**WORKSHEETS (LEMBAR KERJA)**

<b>Mata Kuliah</b>	: Anatomi
<b>Materi</b>	: Anatomi Digesti
<b>NIM&gt;Nama Mahasiswa</b>	: 2110101056/ Aliya Puspita Rizwani

No	Keterangan	Pembahasan
1		<ol style="list-style-type: none"> <li>1. Kelenjar Ludah</li> <li>2. Kelenjar parotis</li> <li>3. Submandibularis (bawah rahang)</li> <li>4. Kelenjar sublingualis (bawah lidah)</li> <li>5. mulut</li> <li>6. amandel</li> <li>7. lidah</li> <li>8. esophagus</li> <li>9. Pankreas</li> <li>10. Lambung</li> <li>11. Saluran pankreas</li> <li>12. hati</li> <li>13. kantung empedu</li> <li>14. Duodenum</li> <li>15. Saluran Empedu</li> <li>16. colon</li> <li>17. transverse colon</li> <li>18. Colon ascendens</li> <li>19. Colon descendens</li> <li>20. Ileum (usus halus)</li> <li>21. Cecum</li> <li>22. Usus buntu</li> <li>23. Rectum/ poros usu</li> <li>24. anus</li> </ol>
		<ol style="list-style-type: none"> <li>1. Esofagus</li> <li>2. Kardia</li> <li>3. Fundus</li> <li>4. selaput Lender</li> <li>5. otot lapisan</li> <li>6. Lambung mukosa</li> <li>7. tubuh perut</li> <li>8. pilorik antrum</li> <li>9. pilorus</li> <li>10. usus dua belas jari (duodenum)</li> </ol>

No	Keterangan	Pembahasan
		 <p>The diagram illustrates the large intestine (colon) and its associated structures. The main components labeled are:</p> <ul style="list-style-type: none"> <li><b>Kolon Transversum</b>: The horizontal part of the large intestine at the top.</li> <li><b>Kolon desendens</b>: The descending part of the large intestine on both the left and right sides.</li> <li><b>Usus buntu</b>: The cecum, a pouch-like structure at the bottom left.</li> <li><b>Rektum</b>: The rectum, the terminal part of the large intestine at the bottom right.</li> </ul> <p><small>Hedi Sasawari</small></p>