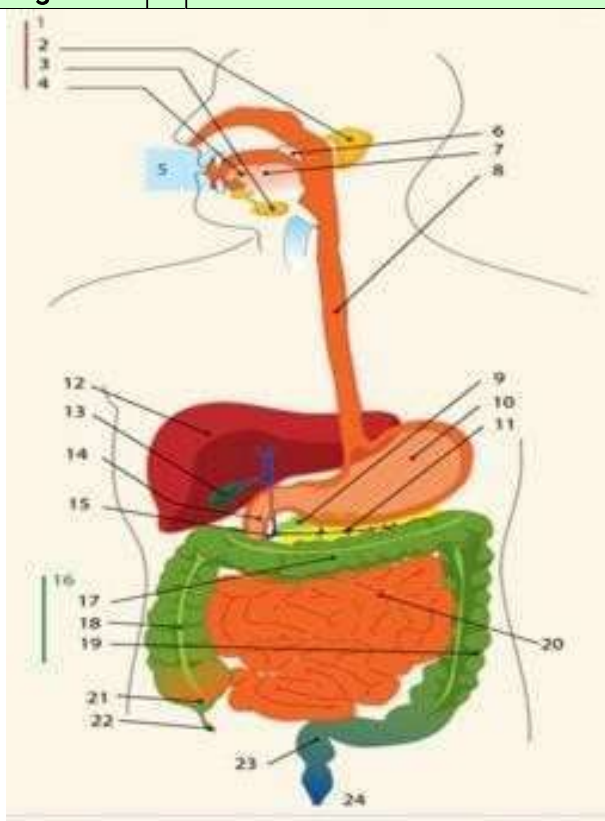
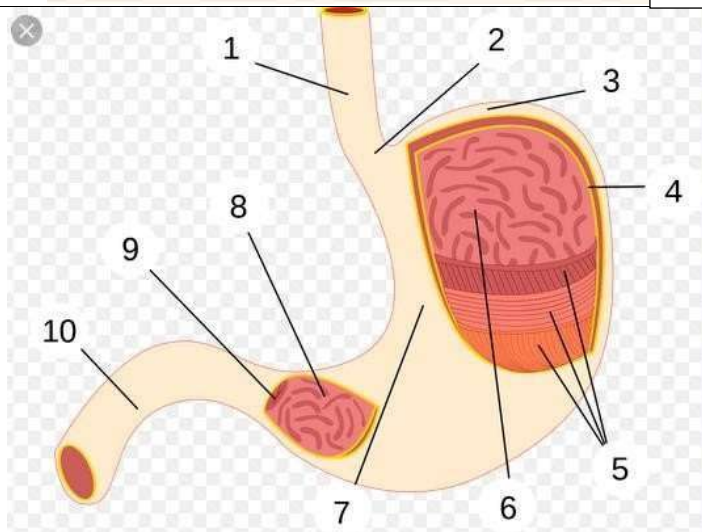
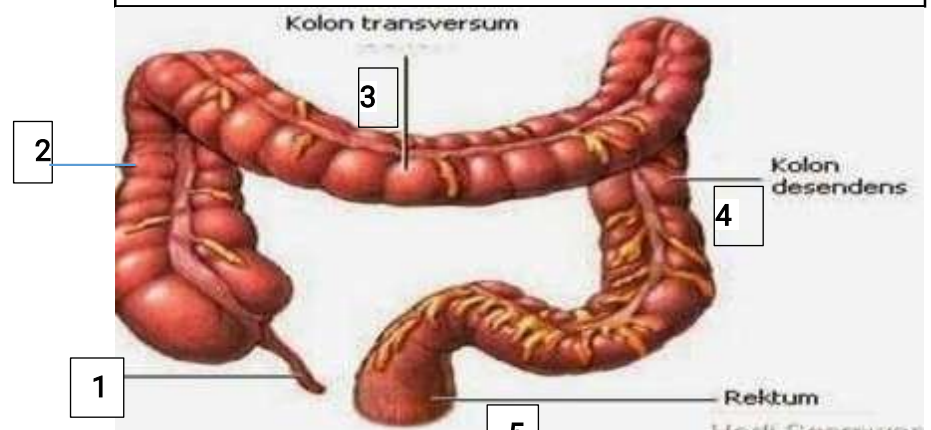


WORKSHEETS (LEMBAR KERJA)

MataKuliah : Anatomi  
 Materi : Anatomi Digesti  
 NIM>Nama : 2110101006/ MONIKAJUMARNIS  
 Mahasiswa

No	Keterangan	Pembahas	KETERANGAN GAMBAR:
1			<p><b>KETERANGAN GAMBAR:</b></p> <ol style="list-style-type: none"> <li>1. Kelenjar ludah</li> <li>2. Parotis</li> <li>3. Submandibularis (bawahrahang)</li> <li>4. Sublingualis (bawah lidah)</li> <li>5. Ronggamulut</li> <li>6. Tekak/faring</li> <li>7. Lidah</li> <li>8. Kerongkongan/esophagus</li> <li>9. Pancreas</li> <li>10. Lambung</li> <li>11. Saluranpancreas</li> <li>12. Hati</li> <li>13. Kantungempedu</li> <li>14. Usus dua belasjari</li> <li>15. Saluranempedu</li> <li>16. Usus tebal/kolon</li> <li>17. Kolon datar(transverse)</li> <li>18. Kolon naik(ascending)</li> <li>19. Kolon turun(descending)</li> <li>20. Usus penyerapan(ileum)</li> <li>21. Sekum</li> <li>22. Umbaicacing</li> <li>23. Poros usus/ rectum</li> <li>24. anus</li> </ol>
			<p><b>KETERANGAN GAMBAR:</b></p> <ol style="list-style-type: none"> <li>1. Esofagus</li> <li>2. Kardia</li> <li>3. Fundus</li> <li>4. Selaputlender</li> <li>5. Ototlapisan</li> <li>6. Lambungmukosa</li> <li>7. Tubuh perut</li> <li>8. Pilorikantrum</li> <li>9. Pylorus</li> <li>10. Usus dua belasjari</li> </ol>

No	Keterangan	Pembahasan
		

**KETERANGAN GAMBAR:**

1. Usus buntu
2. Bagian naik (colonacendens)
3. Bagian mendatar (colontransversum)
4. Bagian menurun (colondesendes)
5. Rektum