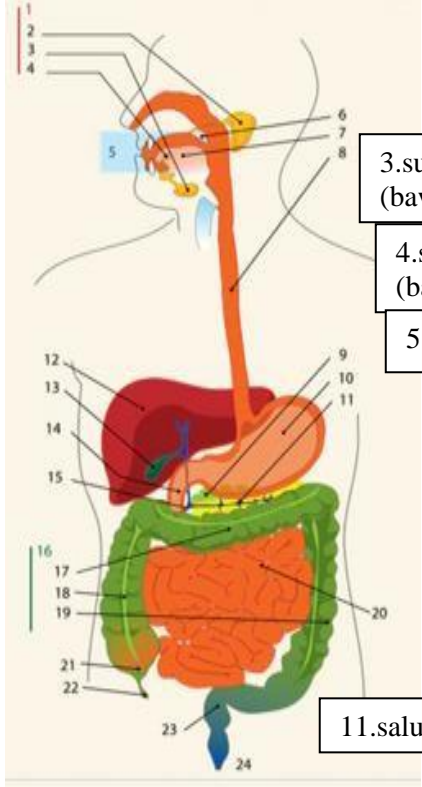
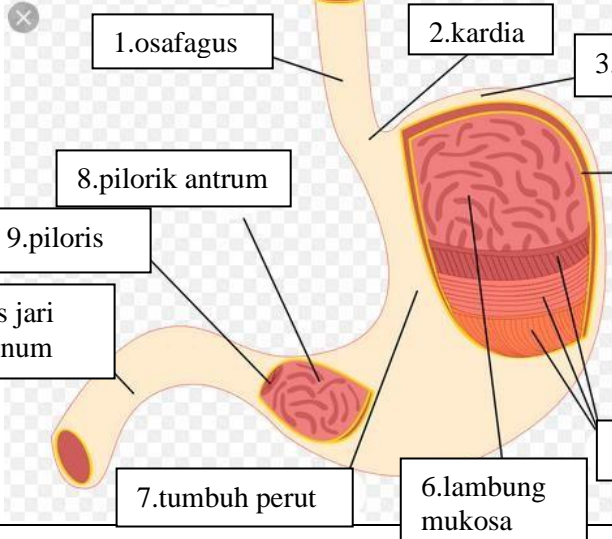


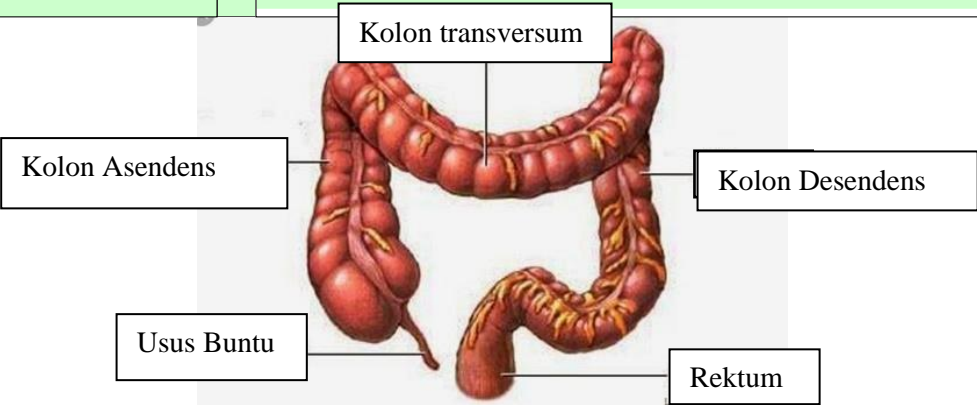
WORKSHEETS (LEMBAR KERJA)

Mata Kuliah	: Anatomi
Materi	: Anatomi Digesti
NIM>Nama Mahasiswa	: 2110101063/Indana Suroya

No	Keterangan	Pembahasan
----	------------	------------

1		<div style="display: flex; flex-direction: row-reverse;"> <div style="margin-right: 10px;"> <p>1.kelenjar</p> <p>2.parotis</p> <p>3.submandibularis (bawah rahang)</p> <p>4.sublingualis (bawah lidah)</p> <p>5.rongga mulut</p> <p>6.amandel</p> <p>7.lidah</p> <p>8.esofagus</p> <p>9.pankreas</p> <p>10.lambung</p> <p>11.saluran pankreas</p> <p>12.hati</p> </div> <div style="margin-right: 10px;"> <p>13.kantung empedu</p> <p>14.duodenum</p> <p>15.saluran empedu</p> <p>16.kolon</p> <p>17.kolon transversum</p> <p>18.kolon aacenden</p> <p>19.kolon descendun</p> <p>20.ileum</p> <p>21.sekum</p> <p>22.appendiks/poros usus</p> <p>23.rektum/poros usus</p> <p>24.anus</p> </div> </div>
---	--	---

	<div style="display: flex; flex-direction: row-reverse;"> <div style="margin-right: 10px;"> <p>1.osafagus</p> <p>2.kardia</p> <p>3.fundus</p> <p>4.selaput lender</p> <p>5.otot lapisan</p> <p>6.lambung mukosa</p> <p>7.tumbuh perut</p> <p>8.pilorik antrum</p> <p>9.piloris</p> <p>10.usus jari (duodenum)</p> </div> </div>
--	---

No	Keterangan	Pembahasan
		 <p>The diagram illustrates the large intestine (colon) and its associated structures. The main components are labeled as follows:</p> <ul style="list-style-type: none"> Kolon transversum: The transverse colon, the upper horizontal part of the large intestine. Kolon Asendens: The ascending colon, the vertical part on the right side. Kolon Desendens: The descending colon, the vertical part on the left side. Usus Buntu: The vermiform appendix, a small projection from the bottom of the cecum. Rektum: The rectum, the terminal part of the large intestine.