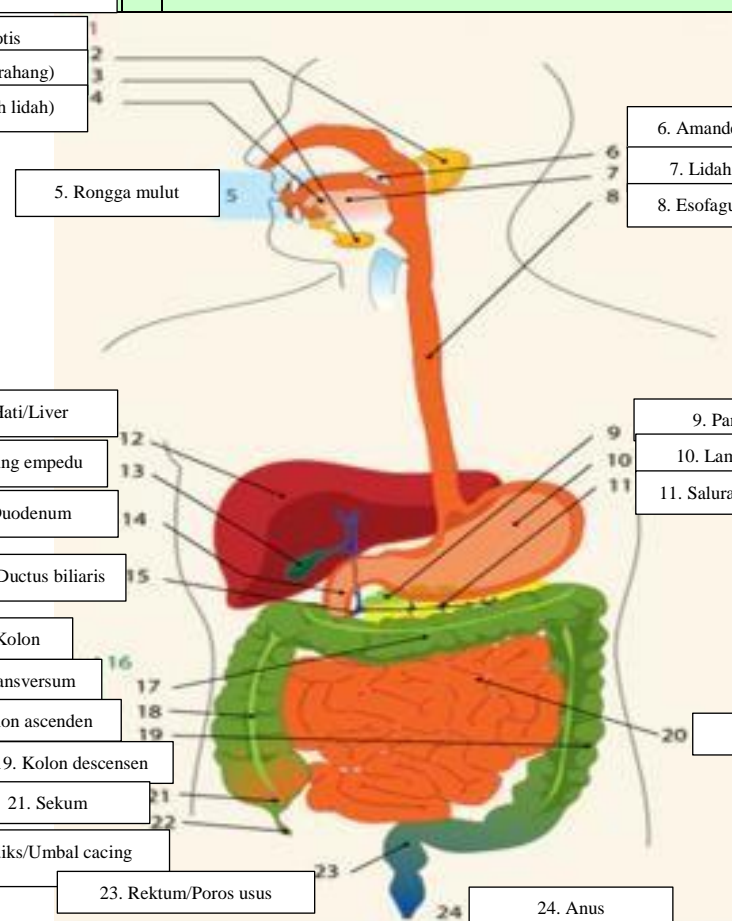
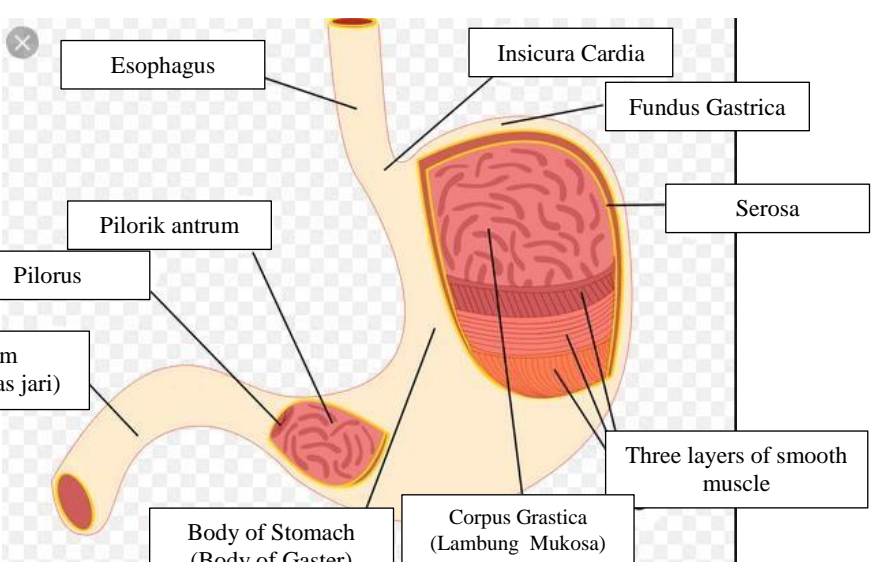
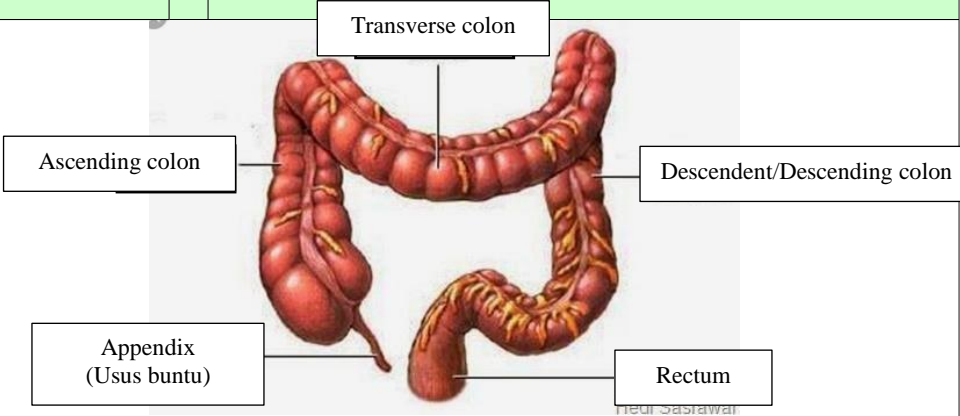


WORKSHEETS (LEMBAR KERJA)

Mata Kuliah	: Anatomi
Materi	: Anatomi Digesti
NIM>Nama Mahasiswa	: 2110101009/Azira Syiffa Ramadhani

No	Keterangan	Pembahasan
1	<p>1. Kelenjar ludah</p> <p>2. Parotis</p> <p>3. Submandibularis (bawah rahang)</p> <p>4. Sublingualis (bawah lidah)</p> <p>5. Rongga mulut</p> <p>12. Hati/Liver</p> <p>13. Kantung empedu</p> <p>14. Duodenum</p> <p>15. Saluran empedu/ Ductus biliaris</p> <p>16. Kolon</p> <p>17. Kolon transversum</p> <p>18. Kolon ascenden</p> <p>19. Kolon descensen</p> <p>21. Sekum</p> <p>22. Appendiks/Umbal cacing</p> <p>23. Rektum/Poros usus</p>	<p>6. Amandel</p> <p>7. Lidah</p> <p>8. Esofagus</p> <p>9. Pankreas</p> <p>10. Lambung (Gaster)</p> <p>11. Saluran Pankreas</p> <p>20. Ileum</p> <p>24. Anus</p> 
	<p>Esophagus</p> <p>Insicura Cardia</p> <p>Fundus Gastrica</p> <p>Serosa</p> <p>Piloric antrum</p> <p>Pylorus</p> <p>Three layers of smooth muscle</p> <p>Body of Stomach (Body of Gaster)</p> <p>Corpus Grastica (Lambung Mukosa)</p> <p>Duodenum (usus dua belas jari)</p>	

No	Keterangan	Pembahasan
		 <p>The diagram illustrates the large intestine (colon) and its associated structures. The main components are labeled as follows:</p> <ul style="list-style-type: none"> Transverse colon: The upper horizontal part of the large intestine. Ascending colon: The vertical part on the right side of the abdomen. Descendent/Descending colon: The vertical part on the left side of the abdomen. Appendix (Usus buntu): A small, finger-like projection from the bottom of the cecum. Rectum: The final straight part of the large intestine, leading to the anus. <p><small>Heul Sasrawai</small></p>