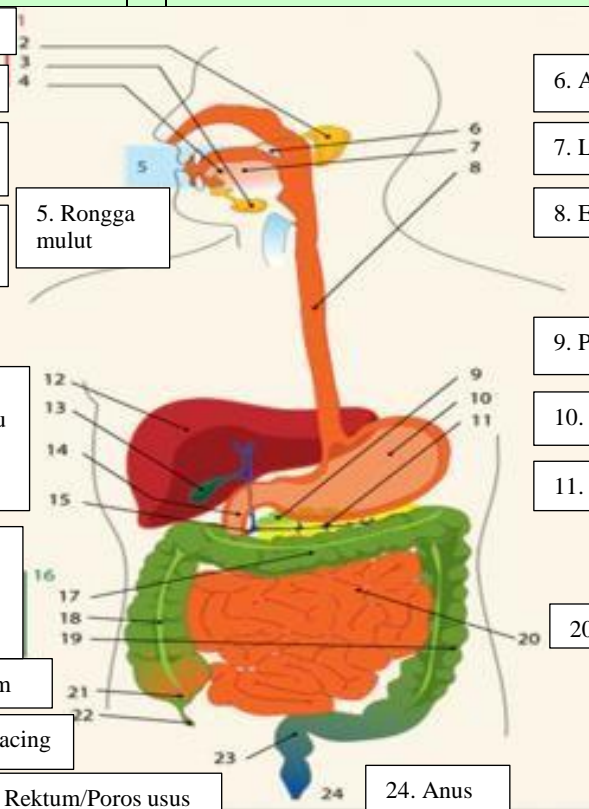
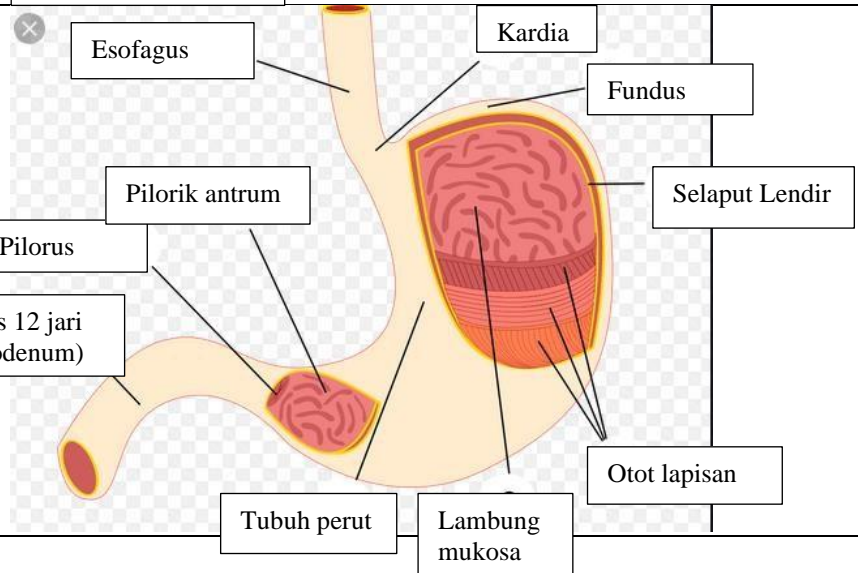
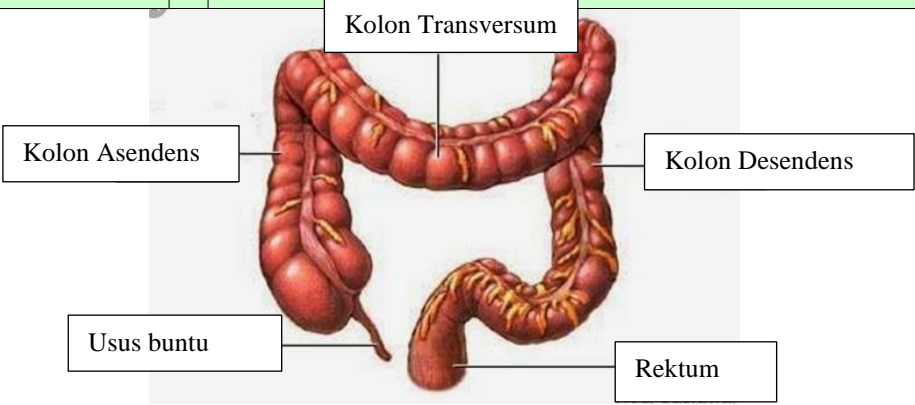


### WORKSHEETS (LEMBAR KERJA)

<b>Mata Kuliah</b>	: <b>Anatomi</b>
<b>Materi</b>	: <b>Anatomi Digesti</b>
<b>NIM&gt;Nama Mahasiswa</b>	: 2110101060/Firsta Fadhlila Putri

No	Keterangan	Pembahasan
<p>1. Kelenjar ludah</p> <p>2. Parotis</p> <p>3. Submandibularis (Bawah rahang)</p> <p>4. Sub lingualis (bawah lidah)</p> <p>12. Hati</p> <p>13. Kantung Empedu</p> <p>14. Duodenum</p> <p>15. Saluran Empedu</p> <p>16. Kolon</p> <p>17. Kolon Transversum</p> <p>18. Kolon ascenden</p> <p>19. Kolon Descenden</p> <p>21. Sekum</p> <p>22. Appendiks/Umbai cacing</p>		<p>6. Amandel</p> <p>7. Lidah</p> <p>8. Esofagus</p> <p>9. Pankreas</p> <p>10. Lambung</p> <p>11. Saluran pankreas</p> <p>20. Ileum</p> <p>23. Rektum/Poros usus</p> <p>24. Anus</p>
		

No	Keterangan	Pembahasan
		 <p>The diagram illustrates the large intestine (colon) and its associated structures. The main components are labeled as follows:</p> <ul style="list-style-type: none"> <li><b>Kolon Transversum</b>: The horizontal section of the large intestine at the top.</li> <li><b>Kolon Asendens</b>: The vertical section of the large intestine on the right side.</li> <li><b>Kolon Desendens</b>: The vertical section of the large intestine on the left side.</li> <li><b>Usus buntu</b>: The vermiform appendix, a small finger-like projection at the end of the cecum.</li> <li><b>Rektum</b>: The final straight section of the large intestine, leading to the rectum.</li> </ul>