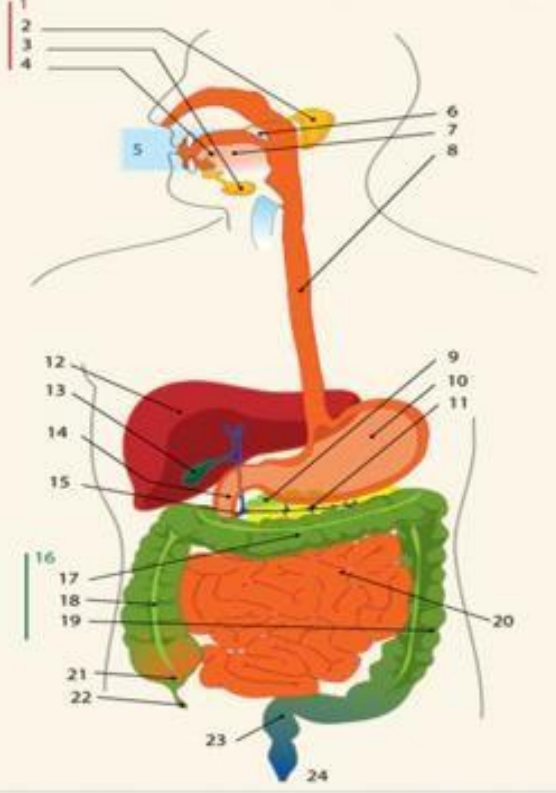
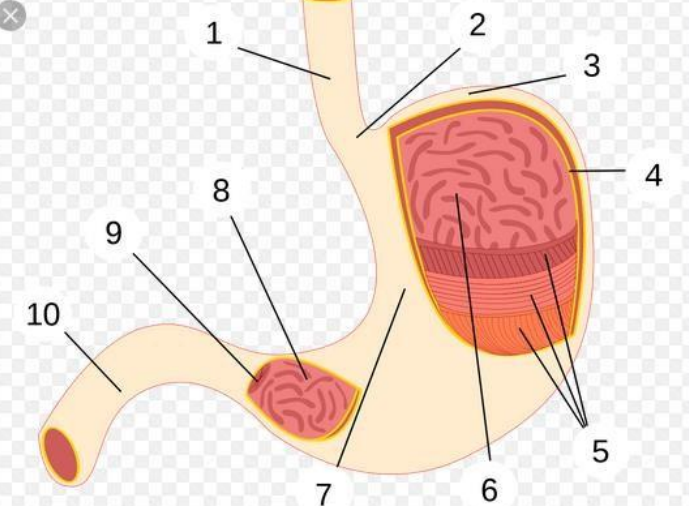
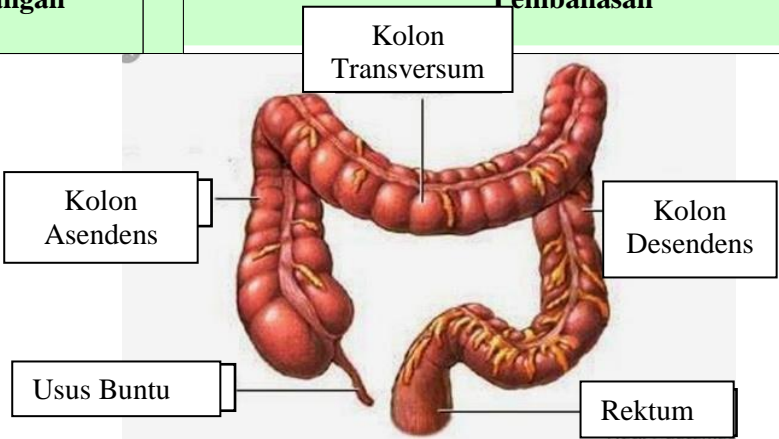


WORKSHEETS (LEMBAR KERJA)

Mata Kuliah	: Anatomi
Materi	: Anatomi Digesti
NIM>Nama Mahasiswa	: Rizfi Pramesi Lalita Fasya

No	Keterangan	Pembahasan																																						
1		<p>Keterangan :</p> <table border="0"> <tr> <td>1. Salivary Glands</td> <td>20. Jejunum</td> </tr> <tr> <td>2. Parotid</td> <td>21. Cecum</td> </tr> <tr> <td>3. Sublingual</td> <td>22. Appendix</td> </tr> <tr> <td>4. Submandibular</td> <td>23. Rectum</td> </tr> <tr> <td>5. Oral Cravity</td> <td>24. Anus</td> </tr> <tr> <td>6. Uvula</td> <td></td> </tr> <tr> <td>7. Tongue</td> <td></td> </tr> <tr> <td>8. Esoophagus</td> <td></td> </tr> <tr> <td>9. Pancreas</td> <td></td> </tr> <tr> <td>10. Stomach</td> <td></td> </tr> <tr> <td>11. Pancreatic Duct</td> <td></td> </tr> <tr> <td>12. Liver</td> <td></td> </tr> <tr> <td>13. Gallbladder</td> <td></td> </tr> <tr> <td>14. Duodenum</td> <td></td> </tr> <tr> <td>15. Common bile duct</td> <td></td> </tr> <tr> <td>16. Colon</td> <td></td> </tr> <tr> <td>17. Transverse Colon</td> <td></td> </tr> <tr> <td>18. Ascending Colon</td> <td></td> </tr> <tr> <td>19. Descending Colon</td> <td></td> </tr> </table>	1. Salivary Glands	20. Jejunum	2. Parotid	21. Cecum	3. Sublingual	22. Appendix	4. Submandibular	23. Rectum	5. Oral Cravity	24. Anus	6. Uvula		7. Tongue		8. Esoophagus		9. Pancreas		10. Stomach		11. Pancreatic Duct		12. Liver		13. Gallbladder		14. Duodenum		15. Common bile duct		16. Colon		17. Transverse Colon		18. Ascending Colon		19. Descending Colon	
1. Salivary Glands	20. Jejunum																																							
2. Parotid	21. Cecum																																							
3. Sublingual	22. Appendix																																							
4. Submandibular	23. Rectum																																							
5. Oral Cravity	24. Anus																																							
6. Uvula																																								
7. Tongue																																								
8. Esoophagus																																								
9. Pancreas																																								
10. Stomach																																								
11. Pancreatic Duct																																								
12. Liver																																								
13. Gallbladder																																								
14. Duodenum																																								
15. Common bile duct																																								
16. Colon																																								
17. Transverse Colon																																								
18. Ascending Colon																																								
19. Descending Colon																																								
		<p>Keterangan :</p> <table border="0"> <tr> <td>1. Esophagus</td> </tr> <tr> <td>2. Kardia</td> </tr> <tr> <td>3. Fundus</td> </tr> <tr> <td>4. Selaput lender</td> </tr> <tr> <td>5. Otot lapisan</td> </tr> <tr> <td>6. Lambung mukosa</td> </tr> <tr> <td>7. Tubuh perut</td> </tr> <tr> <td>8. Pilorik antrum</td> </tr> <tr> <td>9. Pylorus</td> </tr> <tr> <td>10. Usus 12 jari (duodenum)</td> </tr> </table>	1. Esophagus	2. Kardia	3. Fundus	4. Selaput lender	5. Otot lapisan	6. Lambung mukosa	7. Tubuh perut	8. Pilorik antrum	9. Pylorus	10. Usus 12 jari (duodenum)																												
1. Esophagus																																								
2. Kardia																																								
3. Fundus																																								
4. Selaput lender																																								
5. Otot lapisan																																								
6. Lambung mukosa																																								
7. Tubuh perut																																								
8. Pilorik antrum																																								
9. Pylorus																																								
10. Usus 12 jari (duodenum)																																								

No	Keterangan	Pembahasan
		 <p>The diagram illustrates the large intestine (colon) and its associated structures. The main components are labeled as follows:</p> <ul style="list-style-type: none"> Kolon Transversum: The horizontal part of the large intestine at the top. Kolon Asendens: The vertical part of the large intestine on the right side. Kolon Desendens: The vertical part of the large intestine on the left side. Usus Buntu: The cecum, a pouch-like structure at the bottom of the ascending colon. Rektum: The final part of the large intestine, leading to the rectum. <p><small>Hedi Sasrawati</small></p>