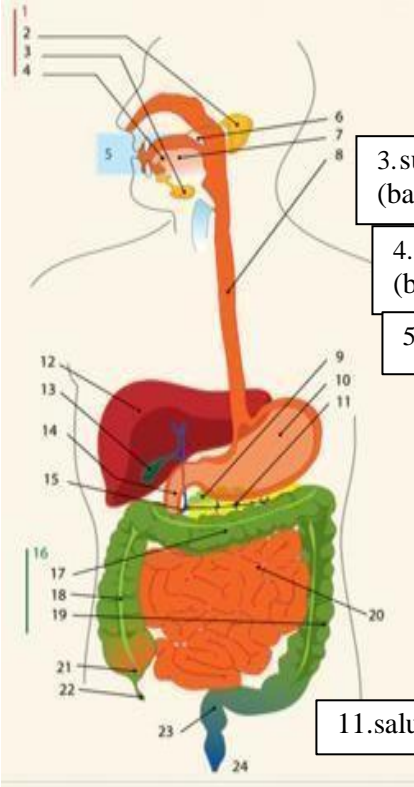
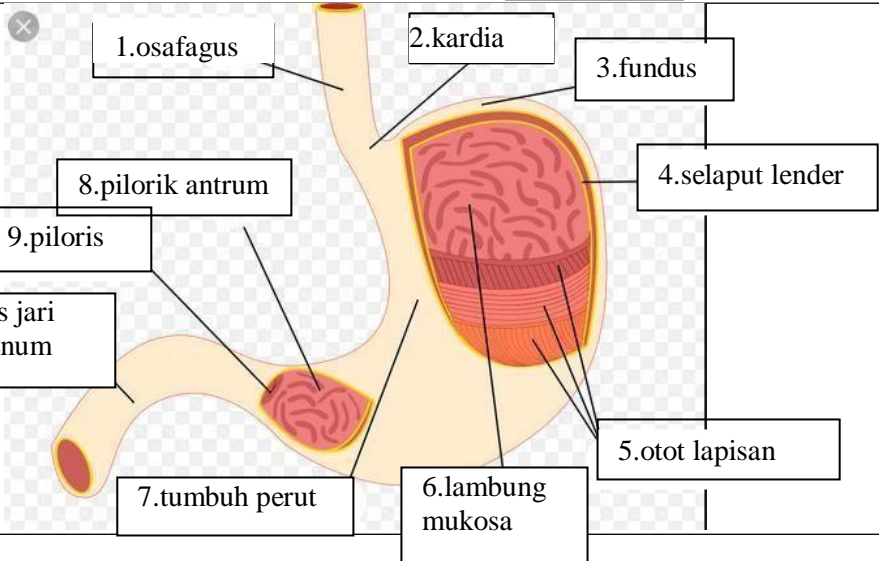
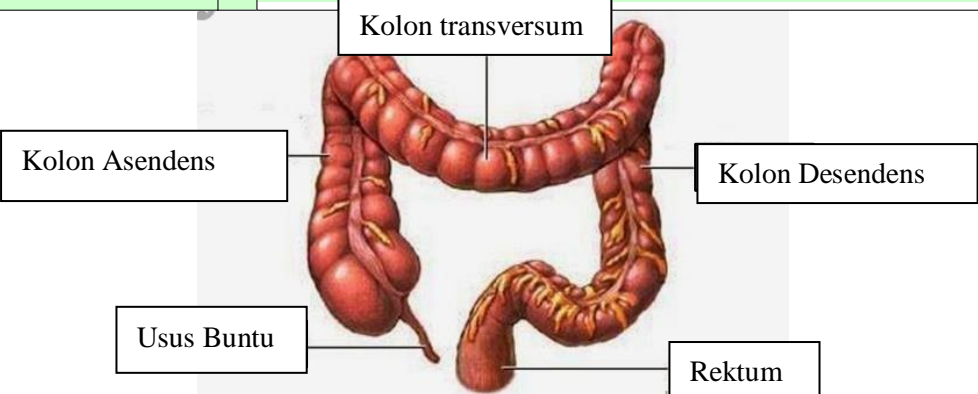


**WORKSHEETS (LEMBAR KERJA)**

<b>Mata Kuliah</b>	: Anatomi
<b>Materi</b>	: Anatomi Digesti
<b>NIM&gt;Nama Mahasiswa</b>	: 2110101046/Oktaviana Rahmawati

No	Keterangan	Pembahasan																								
1		<table border="0"> <tr> <td>1.kelenjar</td> <td>13.kantung empedu</td> </tr> <tr> <td>2.parotis</td> <td>14.duodenum</td> </tr> <tr> <td>3.submandibularis (bawah rahang)</td> <td>15.saluran empedu</td> </tr> <tr> <td>4.sublingualis (bawah lidah)</td> <td>16.kolon</td> </tr> <tr> <td>5.rongga mulut</td> <td>17.kolon transversum</td> </tr> <tr> <td>6.amandel</td> <td>18.kolon aacenden</td> </tr> <tr> <td>7.lidah</td> <td>19.kolon descendun</td> </tr> <tr> <td>8.esofagus</td> <td>20.ileum</td> </tr> <tr> <td>9.pankreas</td> <td>21.sekum</td> </tr> <tr> <td>10.lambung</td> <td>22.appendiks/poros usus</td> </tr> <tr> <td>11.saluran pankreas</td> <td>23.rektum/poros usus</td> </tr> <tr> <td>12.hati</td> <td>24.anus</td> </tr> </table>	1.kelenjar	13.kantung empedu	2.parotis	14.duodenum	3.submandibularis (bawah rahang)	15.saluran empedu	4.sublingualis (bawah lidah)	16.kolon	5.rongga mulut	17.kolon transversum	6.amandel	18.kolon aacenden	7.lidah	19.kolon descendun	8.esofagus	20.ileum	9.pankreas	21.sekum	10.lambung	22.appendiks/poros usus	11.saluran pankreas	23.rektum/poros usus	12.hati	24.anus
1.kelenjar	13.kantung empedu																									
2.parotis	14.duodenum																									
3.submandibularis (bawah rahang)	15.saluran empedu																									
4.sublingualis (bawah lidah)	16.kolon																									
5.rongga mulut	17.kolon transversum																									
6.amandel	18.kolon aacenden																									
7.lidah	19.kolon descendun																									
8.esofagus	20.ileum																									
9.pankreas	21.sekum																									
10.lambung	22.appendiks/poros usus																									
11.saluran pankreas	23.rektum/poros usus																									
12.hati	24.anus																									
																										

No	Keterangan	Pembahasan
		 <p>The diagram illustrates the large intestine (colon) and its associated structures. The main components are labeled as follows:</p> <ul style="list-style-type: none"> <li><b>Kolon transversum</b>: The transverse colon, which is the upper horizontal part of the large intestine.</li> <li><b>Kolon Asendens</b>: The ascending colon, the vertical part on the right side of the abdomen.</li> <li><b>Kolon Desendens</b>: The descending colon, the vertical part on the left side of the abdomen.</li> <li><b>Usus Buntu</b>: The vermiform appendix, a small finger-like projection from the junction of the ascending and transverse colons.</li> <li><b>Rektum</b>: The rectum, the final straight part of the large intestine that leads to the anus.</li> </ul>