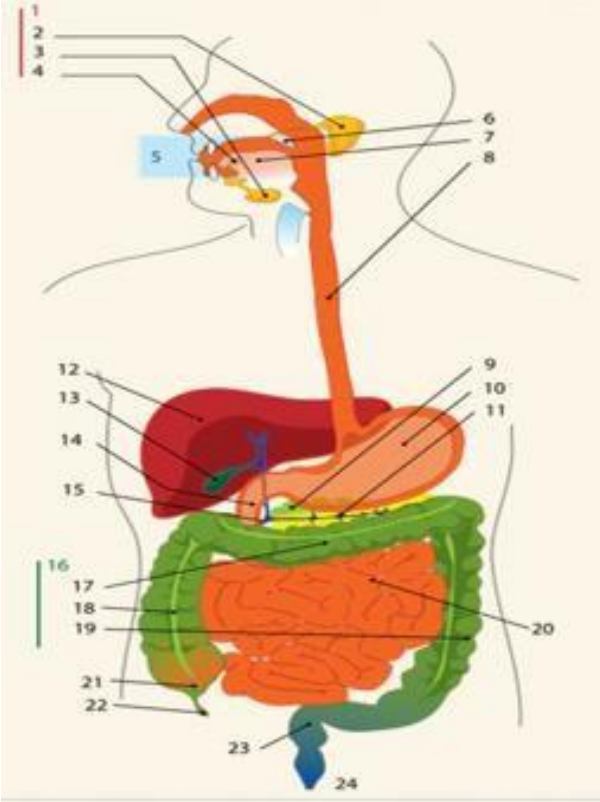
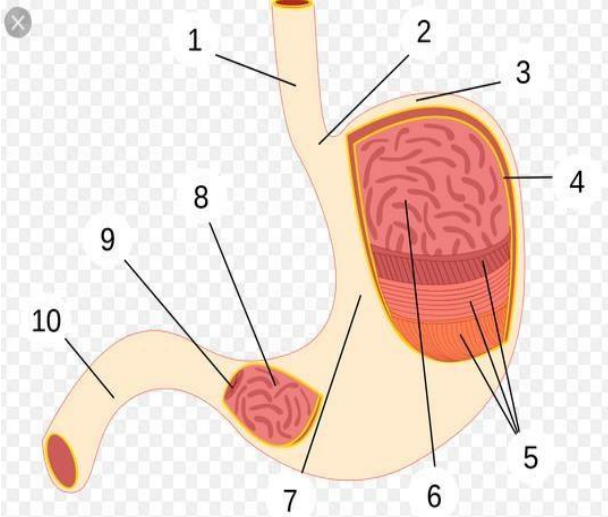
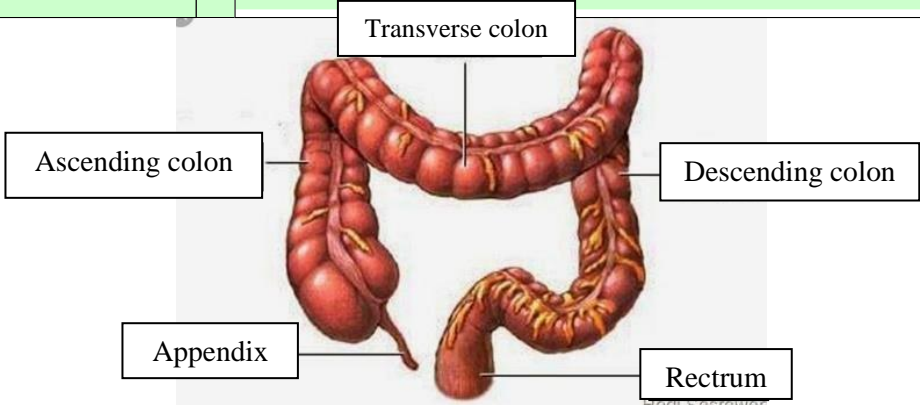


**WORKSHEETS (LEMBAR KERJA)**

<b>Mata Kuliah</b>	: <b>Anatomi</b>
<b>Materi</b>	: <b>Anatomi Digesti</b>
<b>NIM&gt;Nama Mahasiswa</b>	: <b>2110101036/Fauzia Alvian Nurkasanah</b>

No	Keterangan	Pembahasan
1		<ol style="list-style-type: none"> <li>1. Kelenjar ludah</li> <li>2. Parotis</li> <li>3. Submandibularis</li> <li>4. Sublingualis</li> <li>5. Rongga mulut</li> <li>6. Faring</li> <li>7. Lidah</li> <li>8. Esofagus</li> <li>9. Pankreas</li> <li>10. Lambung</li> <li>11. Saluran pankreas</li> <li>12. Hati</li> <li>13. Kantung empedu</li> <li>14. Duodenum</li> <li>15. Saluran empedu</li> <li>16. Kolon</li> <li>17. Kolon datar/transverse</li> <li>18. Kolon naik/ascending</li> <li>19. Kolon turun/descending</li> <li>20. Ileum</li> <li>21. Sekum</li> <li>22. Umbai cacing</li> <li>23. Rektum</li> <li>24. Anus</li> </ol>
		<ol style="list-style-type: none"> <li>1. Esofagus</li> <li>2. Kardia</li> <li>3. Fundus</li> <li>4. Selaput lendir</li> <li>5. Otot lapisan</li> <li>6. Lambung mukosa</li> <li>7. Tubuh perut</li> <li>8. Pilorik antrum</li> <li>9. Pylorus</li> <li>10. Usus dua belas jari (duodenum)</li> </ol>

No	Keterangan	Pembahasan
		 <p>The diagram illustrates the large intestine (colon) and its associated structures. The main components are labeled as follows:</p> <ul style="list-style-type: none"> <li><b>Transverse colon:</b> The upper horizontal part of the large intestine.</li> <li><b>Ascending colon:</b> The vertical part on the right side that ascends.</li> <li><b>Descending colon:</b> The vertical part on the left side that descends.</li> <li><b>Appendix:</b> A small, finger-like projection from the bottom of the cecum.</li> <li><b>Rectum:</b> The final straight part of the large intestine that leads to the anus.</li> </ul> <p><small>Hedi Sasrawati</small></p>