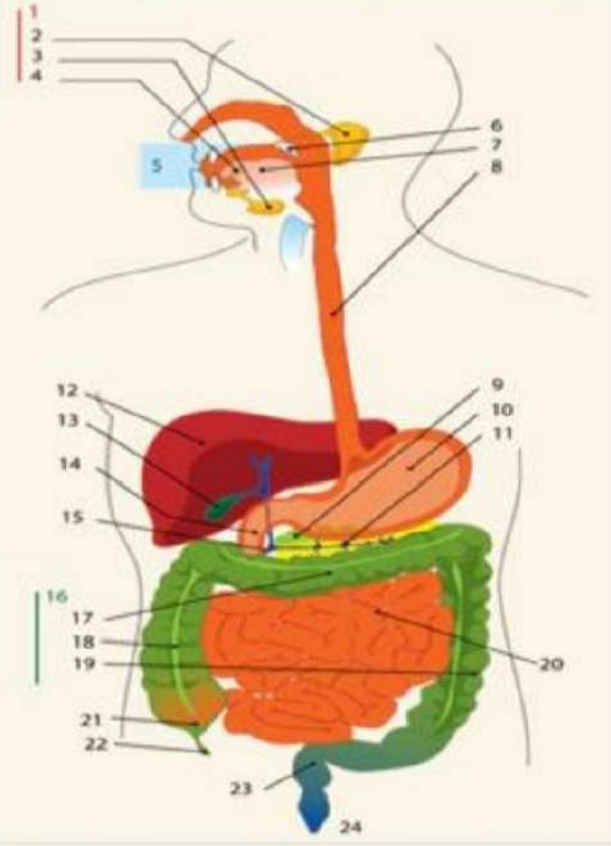
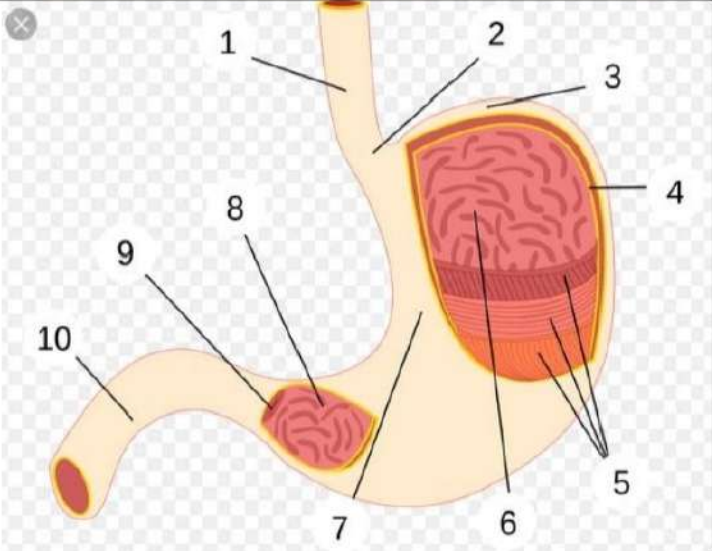


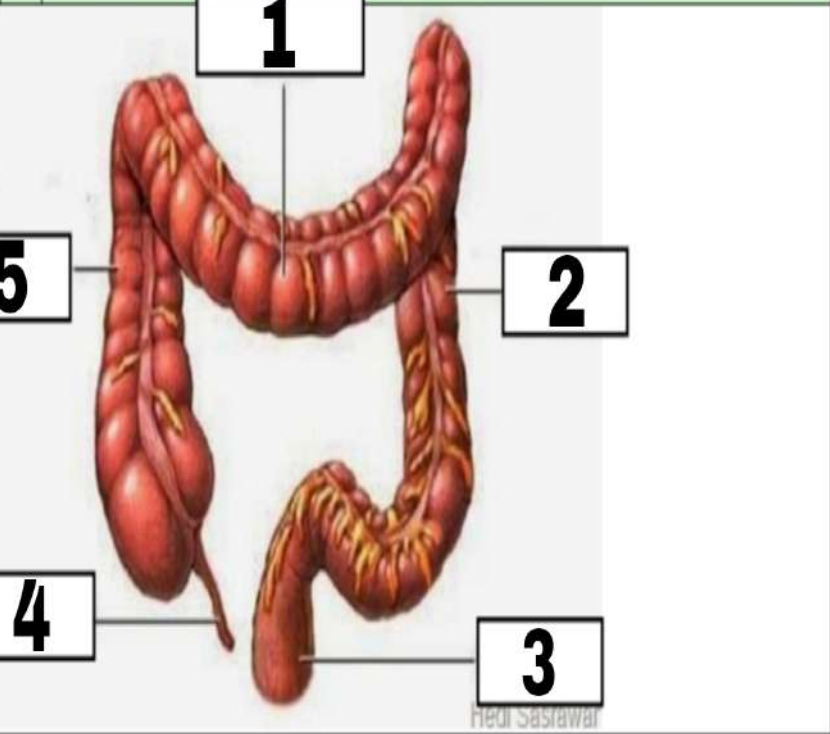
**WORKSHEETS (LEMBAR KERJA)**

<b>Mata Kuliah</b>	<b>: Anatomi</b>
<b>Materi</b>	<b>: Anatomi Digesti</b>
<b>NIM&gt;Nama Mahasiswa</b>	<b>: 2110101039/Ardelia Azmi F</b>

No	Keterangan	Pembahasan
----	------------	------------

1			<ol style="list-style-type: none"> <li>1. Kelenjar Ludah</li> <li>2. Parotis</li> <li>3. Submandibularis ( Bawah Rahang )</li> <li>4. Sublingualis ( Bawah Lidah )</li> <li>5. Rongga mulut</li> <li>6. Amandel</li> <li>7. Lidah</li> <li>8. Esofagus</li> <li>9. Pankreas</li> <li>10. Lambung</li> <li>11. Saluran Pankreas</li> <li>12. Hati</li> <li>13. Kantung Empedu</li> <li>14. Duodenum</li> <li>15. Saluran Empedu</li> <li>16. Colon</li> <li>17. Transverse Colon</li> <li>18. Ascenden Colon</li> <li>19. Descenden Colon</li> <li>20. Ileum</li> <li>21. Sekum</li> <li>22. Appendiks/umbai cacing</li> <li>23. Reknim/poros usus</li> <li>24. Anus</li> </ol>
---	--	---	--

		<ol style="list-style-type: none"> <li>1. Esofagus</li> <li>2. Kardia</li> <li>3. Fundus</li> <li>4. Selaput Lender</li> <li>5. Otot Lapisan</li> <li>6. Lambung Mukosa</li> <li>7. Tubuh Perut</li> <li>8. Pilorik Antrum</li> <li>9. Pylorus</li> <li>10. Usus Dua Belas Jari ( duodenum )</li> </ol>
--	--	---

No	Keterangan	Pembahasan
	<ol style="list-style-type: none"> <li>1. Transverse Colon</li> <li>2. Descending Colon</li> <li>3. Rectum</li> <li>4. Appendix</li> <li>5. Ascending Colon</li> </ol>	 <p>The diagram shows the large intestine (colon) in a reddish-brown color. It is labeled with numbers 1 through 5 in white boxes with black outlines. Label 1 is at the top, pointing to the horizontal transverse colon. Label 2 is on the right side, pointing to the vertical descending colon. Label 3 is at the bottom right, pointing to the rectum. Label 4 is at the bottom left, pointing to the appendix. Label 5 is on the left side, pointing to the vertical ascending colon. The background is light gray.</p>