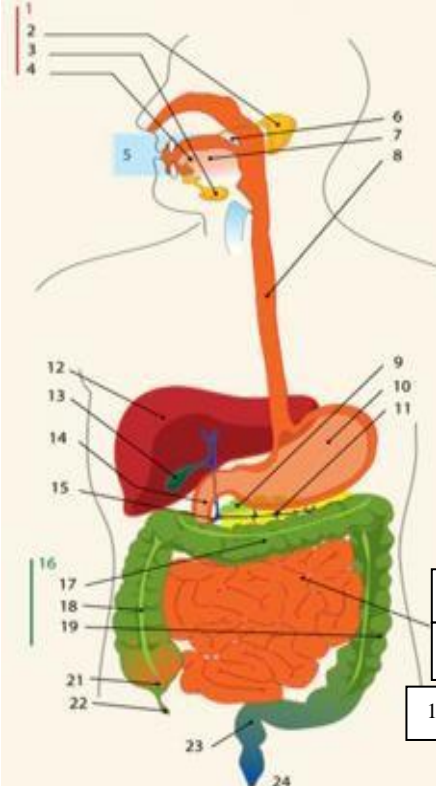
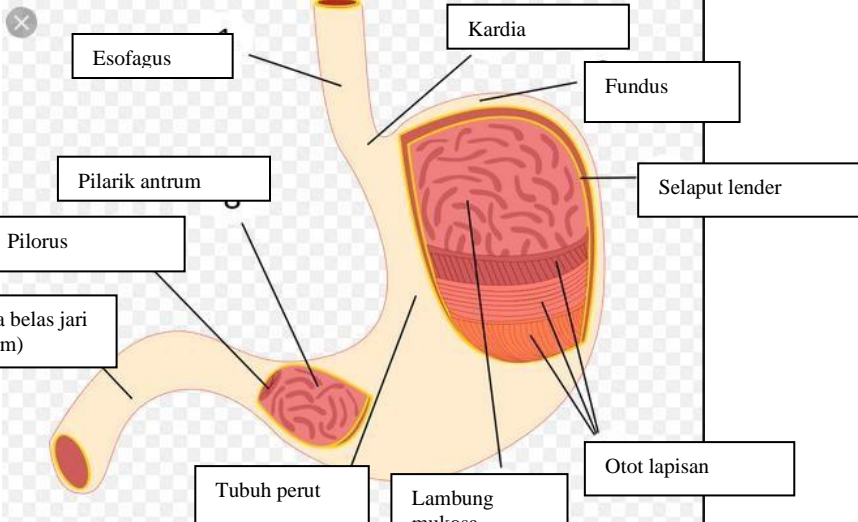
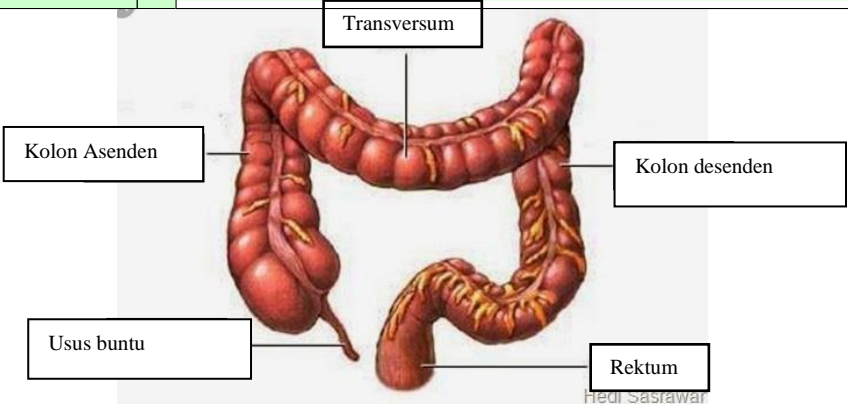


**WORKSHEETS (LEMBAR KERJA)**

<b>Mata Kuliah</b>	: <b>Anatomi</b>
<b>Materi</b>	: <b>Anatomi Digesti</b>
<b>NIM&gt;Nama Mahasiswa</b>	: 2110101041/DWI YANTI

No	Keterangan	Pembahasan																								
1		<table border="0"> <tr> <td>1.Kelenjar parotis</td> <td>13.Kantung empedu</td> </tr> <tr> <td>2.Parotis</td> <td>14.Duodenum</td> </tr> <tr> <td>3.Submandibularis (bawah rahang)</td> <td>15.Saluran empedu</td> </tr> <tr> <td>4.Sublingualis (bawah lidah)</td> <td>16.Kolon</td> </tr> <tr> <td>5.Rongga mulut</td> <td>17.Kolon transversum</td> </tr> <tr> <td>6.Amandel</td> <td>18.Kolon ascenden</td> </tr> <tr> <td>7.Lidah</td> <td>19.Kolon descenden</td> </tr> <tr> <td>8,Esofagus</td> <td>20.Ileum</td> </tr> <tr> <td>9.Pankreas</td> <td>21.Sekum</td> </tr> <tr> <td>10.Lambung</td> <td>22.Appendiks/umbai cacing</td> </tr> <tr> <td>11.Saluran pankreas</td> <td>23.rektum/poros usus</td> </tr> <tr> <td>12.Hati</td> <td>24.Anus</td> </tr> </table>	1.Kelenjar parotis	13.Kantung empedu	2.Parotis	14.Duodenum	3.Submandibularis (bawah rahang)	15.Saluran empedu	4.Sublingualis (bawah lidah)	16.Kolon	5.Rongga mulut	17.Kolon transversum	6.Amandel	18.Kolon ascenden	7.Lidah	19.Kolon descenden	8,Esofagus	20.Ileum	9.Pankreas	21.Sekum	10.Lambung	22.Appendiks/umbai cacing	11.Saluran pankreas	23.rektum/poros usus	12.Hati	24.Anus
1.Kelenjar parotis	13.Kantung empedu																									
2.Parotis	14.Duodenum																									
3.Submandibularis (bawah rahang)	15.Saluran empedu																									
4.Sublingualis (bawah lidah)	16.Kolon																									
5.Rongga mulut	17.Kolon transversum																									
6.Amandel	18.Kolon ascenden																									
7.Lidah	19.Kolon descenden																									
8,Esofagus	20.Ileum																									
9.Pankreas	21.Sekum																									
10.Lambung	22.Appendiks/umbai cacing																									
11.Saluran pankreas	23.rektum/poros usus																									
12.Hati	24.Anus																									
																										

No	Keterangan	Pembahasan
		 <p>The diagram illustrates the large intestine (colon) and its associated structures. The main components are labeled as follows:</p> <ul style="list-style-type: none"> <li><b>Kolon Asenden</b>: The ascending colon, located on the right side of the abdomen.</li> <li><b>Transversum</b>: The transverse colon, the upper horizontal part of the large intestine.</li> <li><b>Kolon desenden</b>: The descending colon, located on the left side of the abdomen.</li> <li><b>Usus buntu</b>: The cecum, a large pouch at the junction of the small and large intestines.</li> <li><b>Rektum</b>: The rectum, the final part of the large intestine that leads to the anus.</li> </ul> <p><small>Hedi Sasitawati</small></p>