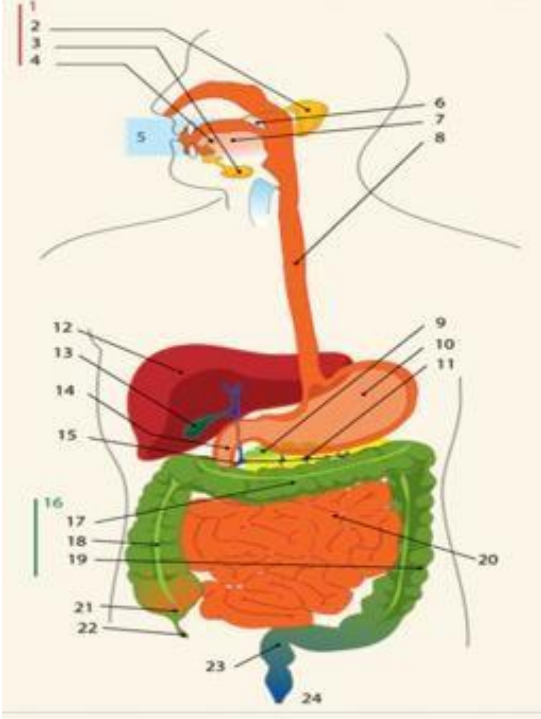
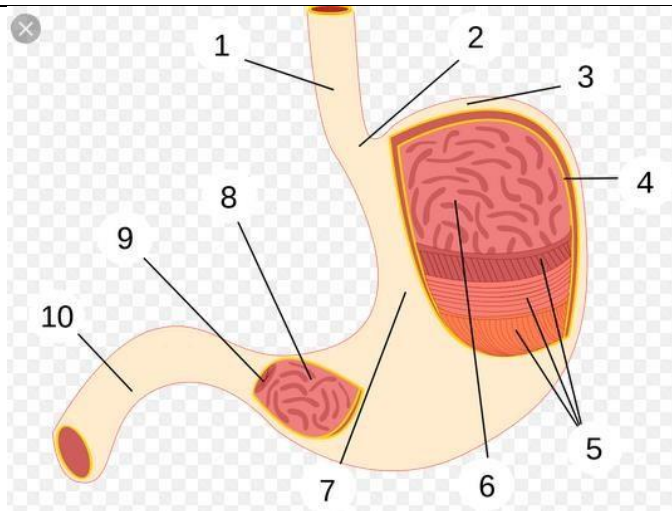


**WORKSHEETS (LEMBAR KERJA)**

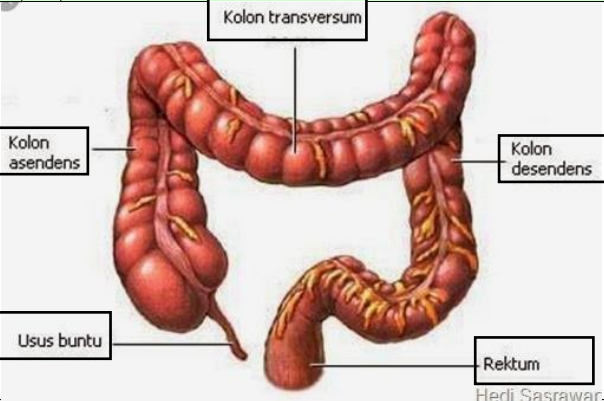
<b>Mata Kuliah</b>	<b>: Anatomi</b>
<b>Materi</b>	<b>: Anatomi Digesti</b>
<b>NIM&gt;Nama Mahasiswa</b>	<b>: 2110101103_ ALFINA FEBRIYANI</b>

No	Keterangan	Pembahasan
1		<p align="center"><b>DIAGRAM SISTEM PENCERNAAN</b></p> <ol style="list-style-type: none"> <li>1. kelenjar ludah</li> <li>2. Parotis</li> <li>3. Submandibularis ( bawah rahang )</li> <li>4. Sublingualis ( bawah lidah )</li> <li>5. Rongga mulut</li> <li>6. Amandel</li> <li>7. Lidah</li> <li>8. Esofagus</li> <li>9. Pangkreas</li> <li>10. Lambung</li> <li>11. Saluran pankreas</li> <li>12. Hati</li> <li>13. Kantung empedu</li> <li>14. Duodenum</li> <li>15. Saluran empedu</li> <li>16. Kolon</li> <li>17. Kolon trasversum</li> <li>18. Kolon ascenden</li> <li>19. Kolon descenden</li> <li>20. Ileum</li> <li>21. Sekum</li> <li>22. Appendiks / umbai cacing</li> <li>23. Rektum / poros usus</li> <li>24. anus</li> </ol>



**BAGIAN LAMBUNG**

1. Esofagus
2. Kardia
3. Fundus
4. Selaput lender
5. Otot lapisan
6. Lambung mukosa
7. Tubuh perut
8. Pilorik antrum
9. Pilorus
10. Usus dua belas jari ( duodenum )

No	Keterangan	Pembahasan
		 <p>The diagram illustrates the large intestine (colon) and its associated structures. The main components are labeled as follows:</p> <ul style="list-style-type: none"> <li><b>Kolon transversum</b>: The transverse colon, which is the upper horizontal part of the large intestine.</li> <li><b>Kolon asendens</b>: The ascending colon, the vertical part on the right side of the body.</li> <li><b>Kolon desendens</b>: The descending colon, the vertical part on the left side of the body.</li> <li><b>Usus buntu</b>: The cecum, a large pouch at the beginning of the large intestine on the right side.</li> <li><b>Rektum</b>: The rectum, the final straight part of the large intestine that leads to the anus.</li> </ul> <p>Hedi Sasrawar</p>