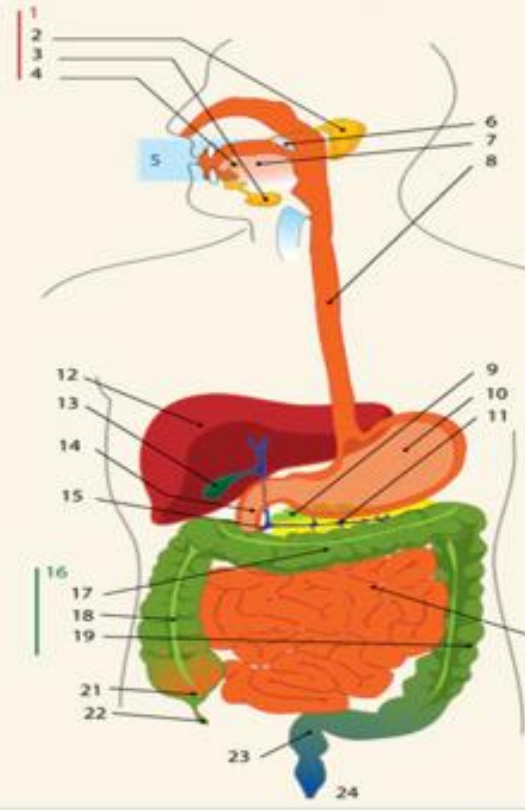
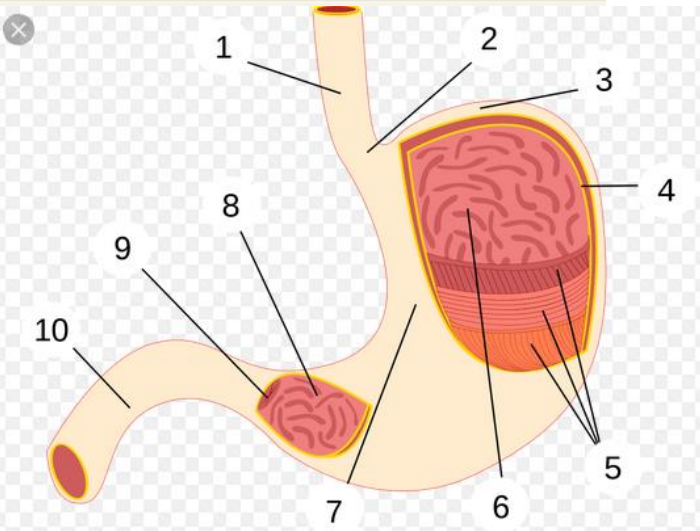
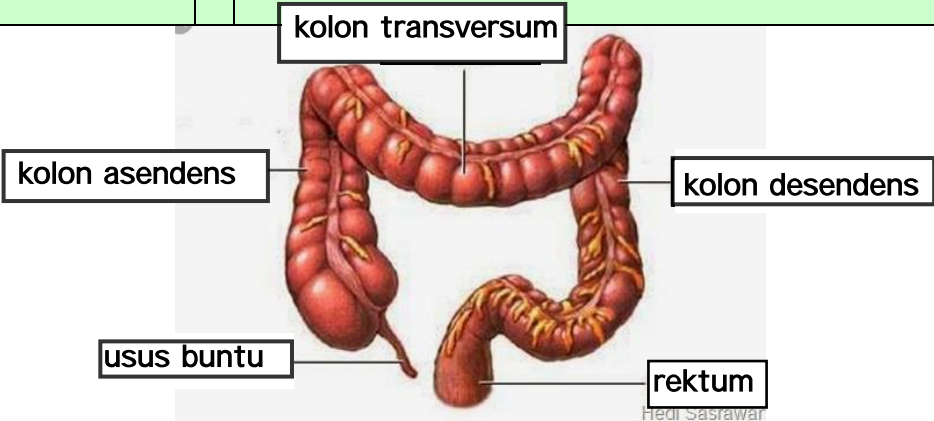


WORKSHEETS (LEMBAR KERJA)

Mata Kuliah	: Anatomi
Materi	: Anatomi Digesti
NIM>Nama Mahasiswa	: selina agustin siswandi 2110101130

No	Keterangan	Pembahasan
1		<ol style="list-style-type: none"> 1. kelenjar ludah 2. parotis 3. submandibularis (bawah rahang) 4. sublingualis (bawah lidah) 5. rongga mulut 6. amandel 7. lidah 8. esofagus 9. pankreas 10. lambung 11. saluran pankreas 12. hati 13. kantung empedu 14. duodenum 15. saluran empedu 16. kolon 17. kolon transversum 18. kolon ascenden 19. kolon descenden 20. ileum 21. sekum 22. appendiks/umbai cacing 23. rektum/poros usus 24. anus
		<ol style="list-style-type: none"> 1. esofagus 2. kardia 3. fundus 4. selaput lender 5. otot lapisan 6. lambung mukosa 7. tubuh perut 8. pilorik antrum 9. pilorus 10. usus dua belas jari (<i>duodenum</i>)

No	Keterangan	Pembahasan
		 <p>The diagram illustrates the large intestine (colon) and its associated structures. The main components are labeled as follows:</p> <ul style="list-style-type: none"> kolon transversum: The transverse colon, which is the upper horizontal part of the large intestine. kolon asendens: The ascending colon, the vertical part on the right side of the abdomen. kolon desendens: The descending colon, the vertical part on the left side of the abdomen. usus buntu: The cecum, a pouch-like structure at the junction of the ascending and transverse colons. rektum: The rectum, the final straight part of the large intestine that leads to the anus. <p><small>Hedi Sasawar</small></p>