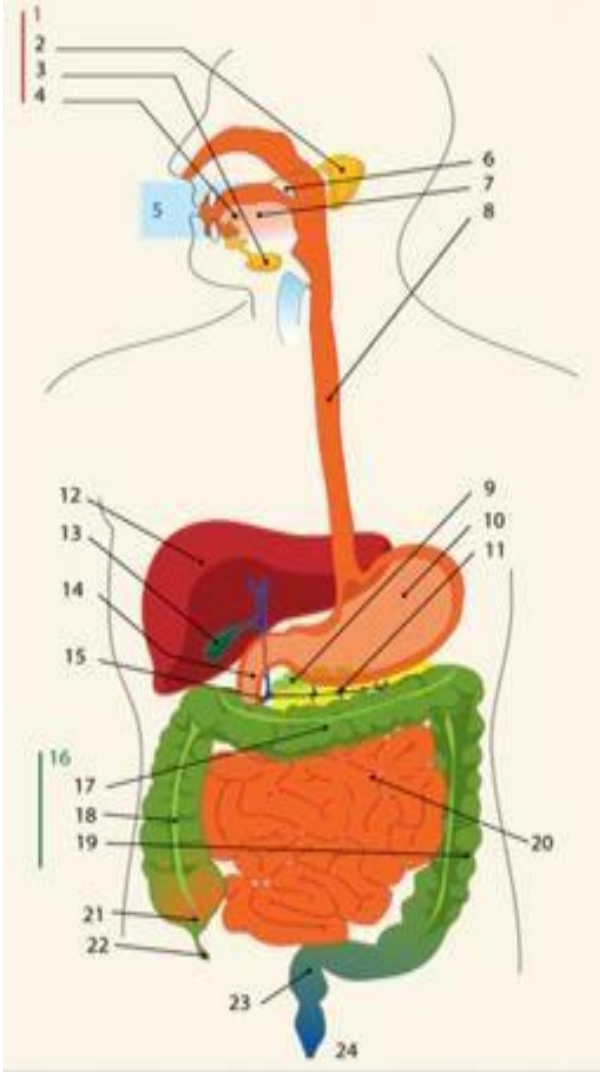
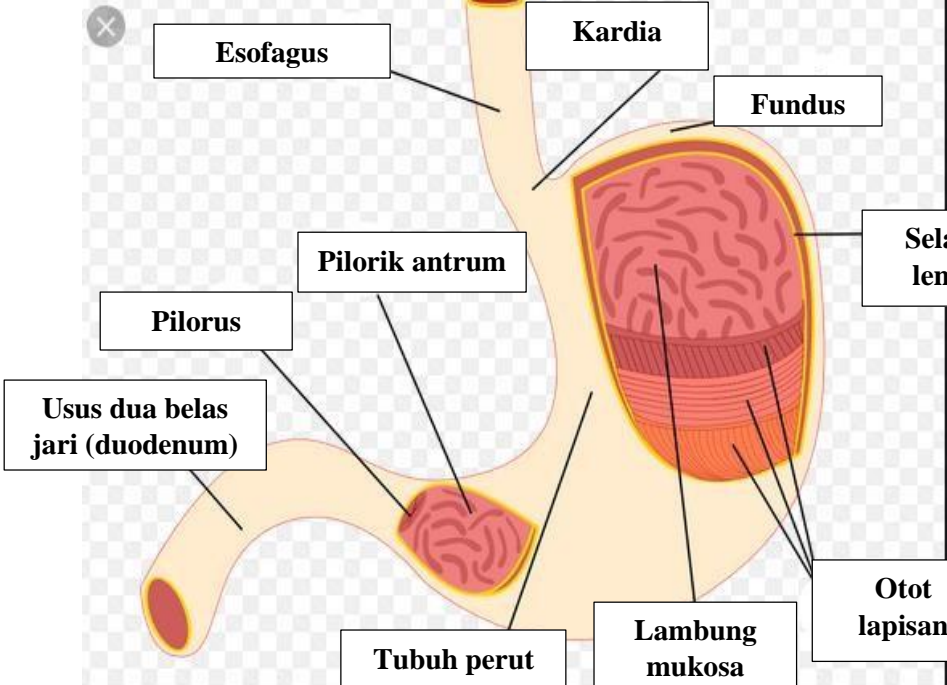


**WORKSHEETS (LEMBAR KERJA)**

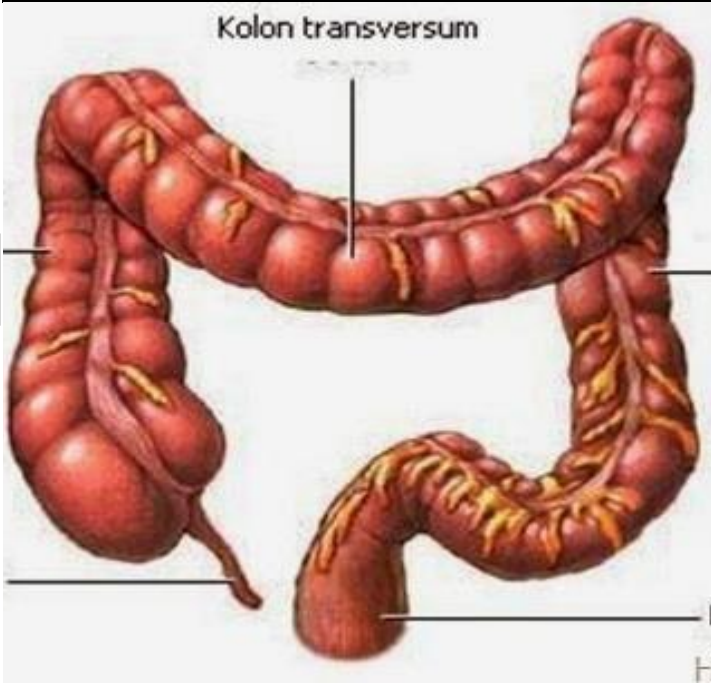
<b>Mata Kuliah</b>	: Anatomi
<b>Materi</b>	: Anatomi Digesti
<b>NIM&gt;Nama Mahasiswa</b>	: 2110101127/Thasya ananda

No	Keterangan	Pembahasan
1		<ol style="list-style-type: none"> <li>1. <b>Kelenjar ludah</b></li> <li>2. <b>Kelenjar parotis</b></li> <li>3. <b>Submandibularis(bawah rahang)</b></li> <li>4. <b>Kelenjar sublingualis(bawah lidah)</b></li> <li>5. <b>mulut</b></li> <li>6. <b>amandel</b></li> <li>7. <b>Lidah</b></li> <li>8. <b>Esophagus</b></li> <li>9. <b>Pankreas</b></li> <li>10. <b>Lambung</b></li> <li>11. <b>Saluran pankreas</b></li> <li>12. <b>Hati</b></li> <li>13. <b>Kantung empedu</b></li> <li>14. <b>Duodenum</b></li> <li>15. <b>Saluran empedu</b></li> <li>16. <b>colon</b></li> <li>17. <b>Transverse colon</b></li> <li>18. <b>Colon asendens</b></li> <li>19. <b>Colon descendens</b></li> <li>20. <b>Ileum (usus halus)</b></li> <li>21. <b>Cecum</b></li> <li>22. <b>Usus buntu</b></li> <li>23. <b>Rectum/poros usu</b></li> <li>24. <b>anus</b></li> </ol>

		
--	--	--

**WORKSHEETS (LEMBAR KERJA)**

**Mata Kuliah** : Anatomi  
**Materi** : Anatomi Digesti  
**NIM>Nama Mahasiswa** : 2110101127/Thasya ananda

No	Keterangan	Pembahasan
	<p data-bbox="225 712 427 797"><b>Kolon desendens</b></p> <p data-bbox="225 1016 427 1079"><b>Usus buntu</b></p>	<p data-bbox="432 416 1145 474"><b>Kolon Transversum</b></p>  <p data-bbox="432 474 1145 1155">An anatomical illustration of the large intestine (colon) in a human body. The illustration shows the characteristic C-shaped structure of the colon. Labels with lines pointing to specific parts are: 'Kolon transversum' at the top horizontal part; 'Kolon desendens' on the right vertical part; 'Usus buntu' (caecum) at the bottom left end; and 'Rektum' at the bottom right end. The text 'Kolon transversum' is also written above the illustration.</p>