

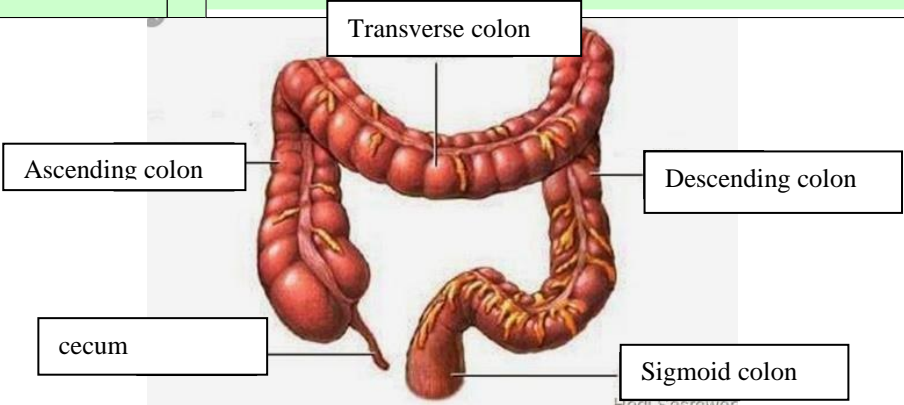
WORKSHEETS (LEMBAR KERJA)

Mata Kuliah	: Anatomi
Materi	: Anatomi Digesti
NIM>Nama Mahasiswa	: MUSYAROFAH 2110101129

No	Keterangan	Pembahasan
----	------------	------------

1. salivary gland
2. parotid gland
3. submandibular gland
4. sublingual gland
5. oral cavity
6. pharynx
7. sublingual gland
8. esophagus
9. pancreas
10. stomach
11. pancreatic duct
12. liver
13. gallbladder
14. duodenum
15. duodenum
16. transverse colon
17. transverse colon
18. ascending colon
19. descending colon
20. jejunum
21. cecum
22. appendix
23. rectum
24. anal canal /anus

1. esophagus
2. cardia
3. fundus
4. Selaput lender
5. Three layers of smooth muscle
-longitudinal layer (outer)
-circulay layer (middle)
-oblique layer (inner)
6. Gastric folds
7. Tubuh perut
8. Pilorik antrum
9. Pyloric orifice
10. duodenum

No	Keterangan	Pembahasan
		 <p>The diagram illustrates the large intestine (colon) with the following labeled parts:</p> <ul style="list-style-type: none"> Transverse colon: The upper horizontal part of the large intestine. Ascending colon: The right vertical part of the large intestine. Descending colon: The left vertical part of the large intestine. Cecum: The large pouch at the beginning of the large intestine on the right side. Sigmoid colon: The lower, S-shaped part of the large intestine on the left side. <p><small>Hedi Sasrawar</small></p>