

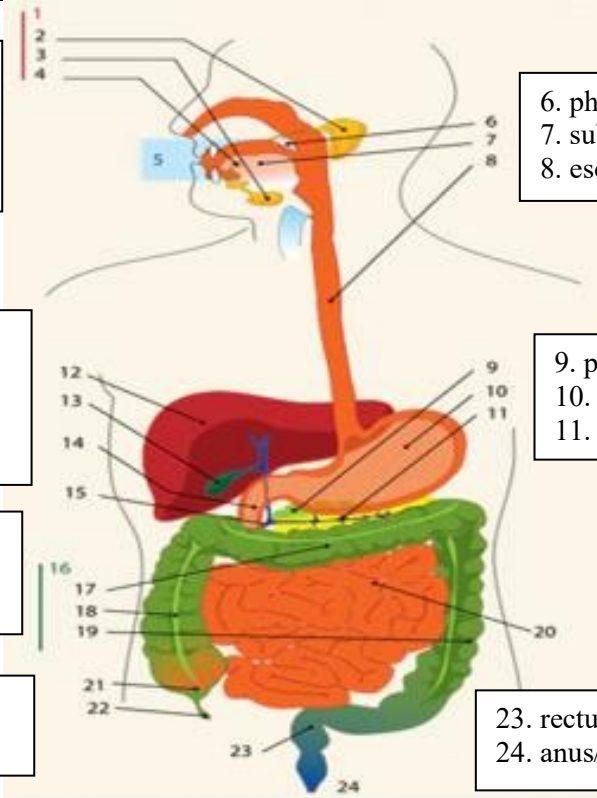
WORKSHEETS (LEMBAR KERJA)

Mata Kuliah	: Anatomi
Materi	: Anatomi Digesti
NIM>Nama Mahasiswa	: 2110101012/Aqila Hana Amadea

No	Keterangan	Pembahasan
----	------------	------------

1

2. parotid gland
3. submandibular gland
4. sublingual gland



6. pharynx
7. sublingual gland
8. esophagus

12. liver
13. gallbladder
14. saluran empedu
15. duodenum

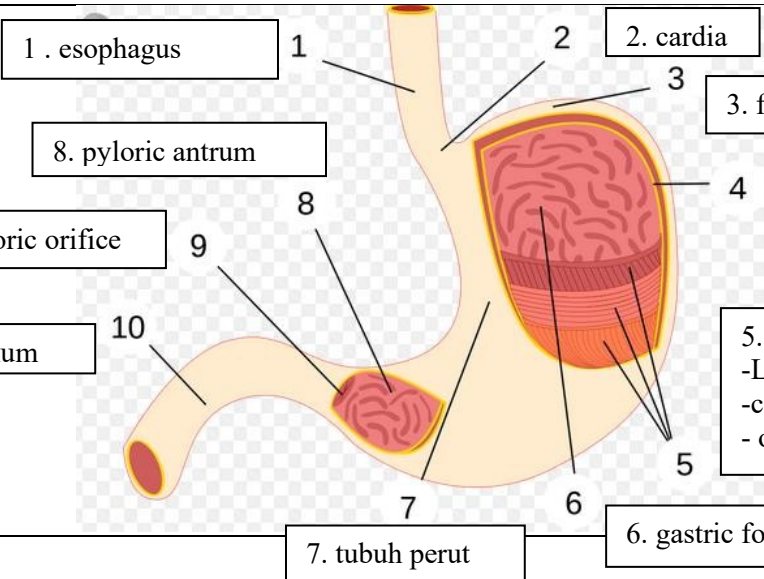
9. pancreas
10. lambung
11. saluran pankreas

17. transversum colon
18. ascenden colon
19. descenden colon

20. jejunum

21. usus buntu (sekum)
22. appendix

23. rectum
24. anus/anal canal



1. esophagus

2. cardia

3. fundus

8. pyloric antrum

4. selaput lender

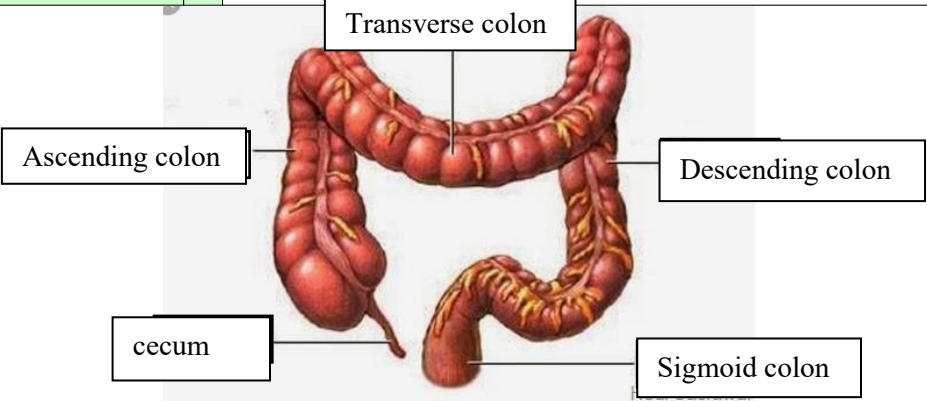
9. pyloric orifice

10. duodenum

5. three layer of smooth muscle
-Longitudinal layer (outer)
-circulay layer (middle)
- oblique layer (inner)

7. tubuh perut

6. gastric folds

No	Keterangan	Pembahasan
		 <p>The diagram illustrates the large intestine (colon) in a human body. It is divided into several parts, each labeled with a box and a line pointing to the corresponding part of the organ:</p> <ul style="list-style-type: none"> Ascending colon: The upper right part of the large intestine. Transverse colon: The upper horizontal part of the large intestine. Descending colon: The lower right part of the large intestine. Cecum: The large, pouch-like structure at the beginning of the large intestine on the right side. Sigmoid colon: The lower left part of the large intestine, which is S-shaped.