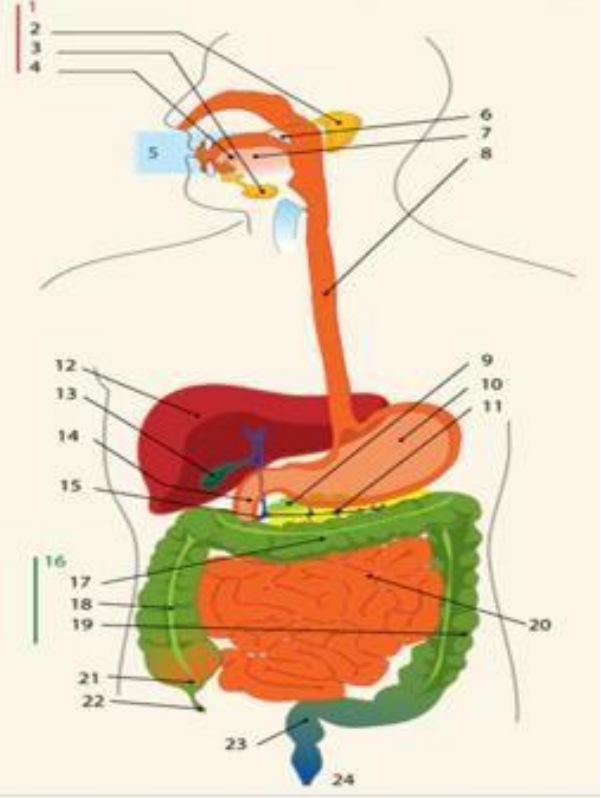
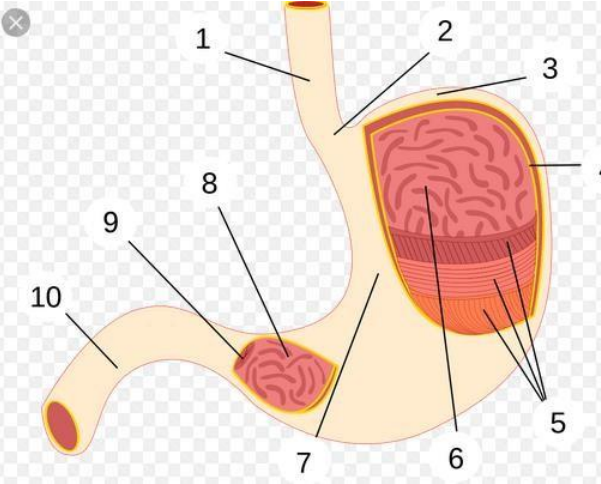
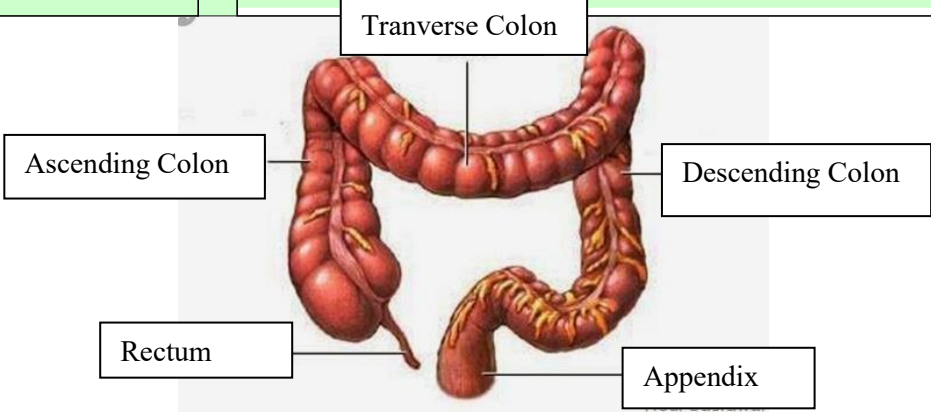


**WORKSHEETS (LEMBAR KERJA)**

<b>Mata Kuliah</b>	: <b>Anatomi</b>
<b>Materi</b>	: <b>Anatomi Digesti</b>
<b>NIM&gt;Nama Mahasiswa</b>	: 2110101026/Aisyah Mutiara Agustin

No	Keterangan	Pembahasan
1		<ol style="list-style-type: none"> <li>1. Salivary glands</li> <li>2. Parotid</li> <li>3. Submandibular</li> <li>4. Sublingual</li> <li>5. Mouth</li> <li>6. Sinus</li> <li>7. Oral Cavity</li> <li>8. Esophagus</li> <li>9. Pancreas</li> <li>10. Ventriculus</li> <li>11. Pancreatic duct</li> <li>12. Liver</li> <li>13. Gallbladder</li> <li>14. Duodenum</li> <li>15. Common bile duct</li> <li>16. Large Intestine</li> <li>17. Transverse colon</li> <li>18. Ascending colon</li> <li>19. Descending colon</li> <li>20. Small intestine</li> <li>21. Cecum</li> <li>22. Vermiform Appendix</li> <li>23. Rectum</li> <li>24. Anal canal</li> </ol>
		<ol style="list-style-type: none"> <li>1. Esophagus</li> <li>2. Cardia</li> <li>3. Fundus</li> <li>4. Selaput lendir</li> <li>5. Lapisan otot</li> <li>6. Mukosa lambung</li> <li>7. Tubuh lambung</li> <li>8. Philorik antrum</li> <li>9. Pylorus</li> <li>10. duodenum</li> </ol>

No	Keterangan	Pembahasan
		 <p>The diagram illustrates the large intestine (colon) and its associated structures. The main components are labeled as follows:</p> <ul style="list-style-type: none"> <li><b>Ascending Colon:</b> The upper right portion of the large intestine.</li> <li><b>Transverse Colon:</b> The upper horizontal portion of the large intestine.</li> <li><b>Descending Colon:</b> The lower right portion of the large intestine.</li> <li><b>Rectum:</b> The final straight portion of the large intestine.</li> <li><b>Appendix:</b> A small, finger-like projection from the junction of the cecum and ascending colon.</li> </ul>